Journal of Medical Microbiology (2010), **59**, 610–613 DOI 10.1099/jmm.0.017194-0

Case Report

Protein-losing enteropathy and hypogammaglobulinaemia as first manifestations of disseminated histoplasmosis coincident with *Nocardia* infection

Jen Kok,[1,2] Sharon C. A. Chen,[1,2] Lyndal Anderson,[3] Lucinda Berglund,[4] Sue Sleiman,[2] Alan Moss,[5] Michael Bourke,[5] David Fulcher[4] and Nicole Gilroy[1]

Correspondence
Jen Kok
jen.kok@swahs.health.nsw.gov.au

[1]Centre for Infectious Diseases and Microbiology, Westmead Hospital, Westmead, NSW 2145, Australia

[2]Centre for Infectious Diseases and Microbiology Laboratory Services, Westmead Hospital, Westmead, NSW 2145, Australia

[3]Department of Anatomical Pathology and Cytology, Institute of Clinical Pathology and Medical Research, Westmead Hospital, Westmead, NSW 2145, Australia

[4]Department of Immunology, Westmead Hospital, Westmead, NSW 2145, Australia

[5]Department of Gastroenterology and Hepatology, Westmead Hospital, Westmead, NSW 2145, Australia

Received 29 October 2009
Accepted 1 February 2010

Disseminated histoplasmosis and nocardiosis typically affect immunocompromised hosts. We report a case of gastrointestinal and adrenal histoplasmosis, presenting as protein-losing enteropathy and hypogammaglobulinaemia, coincident with *Nocardia* infection, in a HIV-negative patient in whom a specific immunological defect could not be identified. Clinicians in areas of non-endemicity should be vigilant for rare manifestations of histoplasmosis.

Introduction

Histoplasma and *Nocardia* are ubiquitous, environmental pathogens. In endemic areas such as the Midwest of the United States, the fungus *Histoplasma capsulatum* most commonly causes localized pulmonary disease whilst disseminated histoplasmosis (DH) typically occurs in patients with HIV/AIDS or other immunodeficiencies (Kauffman, 2007; Suh *et al.*, 2001). DH has also been reported in persons with inherited humoral and cellular immunodeficiencies, including defects in the interferon gamma (IFN-γ) receptor–interleukin 12 axis and the hyper-IgM or hyper-IgE syndromes (Antachopoulos *et al.*, 2007; Zerbe & Holland, 2005). Symptomatic gastrointestinal (GI) histoplasmosis is uncommon (3–12 % of patients), although autopsy series have shown that GI tract involvement is frequent in HIV/AIDS patients (Kauffman, 2007; Wheat *et al.*, 1990). The manifestations of GI infection in other patient groups are not well defined.

Nocardia species cause opportunistic infections in the lungs and central nervous system, but also affect individuals without immune-compromise. Common pathogenic species include *Nocardia farcinica*, *Nocardia nova* and *Nocardia brasiliensis*. In Australia, localized cutaneous disease is most frequently due to *N. brasiliensis*, though any species may cause disseminated infection (Georghiou & Blacklock, 1992; Brown-Elliott *et al.*, 2006).

We report an unusual case of DH, coincident with cutaneous nocardiosis, with first manifestations of hypogammaglobulinaemia secondary to protein-losing enteropathy. Typically associated with immune-compromise, the two entities arose in an apparently healthy host. Clinicians should be alert to atypical manifestations of histoplasmosis, and exclude the possibility of underlying immunodeficiency.

Case report

A 40-year-old white male was admitted to hospital with a 5-month history of recurrent left thigh abscesses, fever and anorexia. Despite broad-spectrum antibacterial therapy and multiple surgical debridements, the abscesses failed to resolve. No pathogen was isolated from surgical specimens. Five years earlier, the patient was extensively investigated for diarrhoea and post-prandial bloating associated with protein-losing enteropathy and hypogammaglobulinaemia.

Abbreviations: DH, disseminated histoplasmosis; GI, gastrointestinal; IFN-γ, interferon gamma.

 017194 © 2010 SGM *Printed in Great Britain*

A diagnosis of primary intestinal lymphangiectasia was made, based on a small bowel series demonstrating 'flocculation' of barium in the ileum, in the absence of any abnormality on upper and lower GI endoscopic examination. Medium-chain triglyceride supplementation was commenced with little clinical response. The patient worked as a landscaper, pursued recreational caving but had not travelled outside Australia. There was no family history of immunodeficiency or previous infections, nor of consanguinity.

The patient was cachectic and febrile, and had marked lower limb oedema. There were multiple, large suppurative abscesses in the left thigh associated with inguinal lymphadenopathy. Physical examination was otherwise unremarkable.

Laboratory studies included: total protein, 57 g l^{-1} (normal range 63–84 mg l^{-1}); albumin, 18 g l^{-1} (35–53 g l^{-1}); and 25-hydroxy-vitamin D, 11 nmol l^{-1} (37–131 nmol l^{-1}).

Magnetic resonance imaging (MRI) of the left leg confirmed an abscess 3×2.3 cm in diameter in the inguinal region and two similar-sized abscesses in the quadriceps muscles. A thoracic CT scan revealed multiple nodules up to 25 mm in diameter in both lung fields and reactive mediastinal lymphadenopathy. MRI of the brain was normal. Microscopy of abscess material collected at open biopsy of the leg lesions revealed thin, branching, Gram-positive rods. Culture grew an aerobic actinomycete identified as *Nocardia* sp. by standard phenotypic-based methods (Brown-Elliott *et al.*, 2006). DNA sequence analysis of the 16S rRNA gene also assigned the isolate as '*Nocardia* sp.' since its 16S rDNA sequence yielded 99 % similarity to those of multiple species of *Nocardia* in the GenBank database (BLASTN 2.2.10; http://www.ncbi.nlm.nih.gov).

Investigations were undertaken to reassess the diagnosis of 'intestinal lymphangiectasia'. Protein-losing enteropathy was confirmed by an elevated stool alpha-1-antitrypsin level of 51 mg l^{-1} (normal range $<$1.5 mg l^{-1}) and technetium-99m dextran scan demonstrating focal concentration in distal small bowel loops consistent with GI protein loss. Push enteroscopy showed macroscopically dilated lacteals in the jejunal mucosa (Fig. 1). Histopathological examination of duodenal and jejunal biopsy specimens revealed villi distended with well-formed granulomata and sheets of foamy macrophages containing ovoid, budding yeast forms 2–4 μm in diameter which stained with methenamine silver (Fig. 2). *H. capsulatum* was cultured from these specimens. Histoplasmin 'H' and 'M' antigens (Fungal Immunodiffusion System; Meridian Bioscience) were detected, but blood cultures were negative for the fungus and bone marrow examination revealed no granulomas or organisms. An abdominal CT scan revealed bilateral homogeneous adrenal masses (6.2 cm diameter) consistent with infiltration by *Histoplasma*, but specimens obtained by fine needle aspiration were negative on culture and nucleic acid testing (Lau *et al.*, 2007). A normal cortisol response was observed with adrenocorticotropic hormone stimulation.

Fig. 1. Endoscopic images showing dilated lacteals in the jejunum.

Investigations for possible immunodeficiency were unfruitful. Serum IgG level was low at 3.06 g l^{-1} (normal range 6.1–15.5 g l^{-1}) consistent with protein-losing enteropathy, but IgM and IgE levels were normal, whilst IgA levels were above normal at 6.32 g l^{-1} (0.8–5.3 g l^{-1}). Total lymphocyte count was mildly reduced at 900 cells μl^{-1} (1000–4000 cells μl^{-1}). Total monocyte count, determined by CD14 expression on a single layer flow cytometry analysis platform, was 194 cells μl^{-1}, within the lower limit of the normal range. The CD4 count was 344 cells μl^{-1}

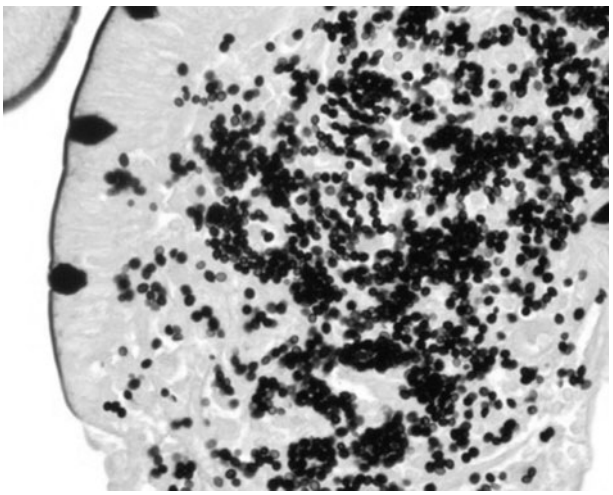

Fig. 2. Diffuse sheets of small (2–4 μm diameter) ovoid, yeast-like organisms in jejunal tissue visualized by methenamine silver staining. Original magnification ×40.

(380–1390 cells μl^{-1}), representing 39 % (37–63 %) of total lymphocytes, but CD3 and CD8 proportions were unremarkable. The B-cell proportion was initially low at 0.7 %, but this normalized following treatment. The NK cell fraction was normal and HIV antibody test was negative. The following conditions were excluded: chronic granulomatous disease (normal neutrophil oxidative metabolism as measured by dihydrorhodamine reduction); X-linked hyper-IgM syndrome (normal induced CD40 ligand expression on T cells, and raised IgA levels); Mendelian susceptibility to mycobacterial disease (normal expression of IFN-γ receptor I on monocytes, normal phosphorylated STAT-1 response of T cells to IFN-γ stimulation, normal phosphorylated STAT-4 response after interleukin 12 signalling of activated T cells); X-linked agammaglobulinaemia (DNA sequencing of the Bruton's tyrosine kinase gene); hyper-IgE syndrome (lack of other manifestations, normal IgE level).

Treatment for DH was initiated with liposomal amphotericin B for 2 weeks, followed by oral itraconazole, with the intention of continuing for a minimum of 2 years (Wheat *et al.*, 2007). The nocardiosis was initially treated with a combination of meropenem and oral trimethoprim/sulfamethoxazole for 2 weeks, followed by trimethoprim/sulfamethoxazole as a single agent. After 6 months of combined antibacterial and antifungal treatment, the patient's skin abscesses completely resolved, the diarrhoea and post-prandial bloating significantly improved and he reported a weight gain of 5 kg. Repeat CT scans showed the persistence of only a single small pulmonary nodule and substantial reduction in size of both adrenal lesions. Examination of subsequent jejunal biopsy specimens demonstrated normal villous architecture; however, *Histoplasma* organisms were still visualized within the villi although cultures were negative. Repeat technetium-99m dextran images showed substantial improvement in protein-losing enteropathy. Serum albumin improved to 29 g l^{-1}; however, IgG has remained at pre-diagnosis levels.

Discussion

The patient described herein is notable for having two opportunistic infections in the absence of an identifiable immune deficiency; both DH and nocardiosis typically affect immunocompromised patients (Kauffman, 2007; Brown-Elliott *et al.*, 2006). Furthermore, he presented with a highly unusual form of GI histoplasmosis – protein-losing enteropathy and hypogammaglobulinaemia. Histoplasmosis is rare in non-endemic countries such as Australia (Hunt *et al.*, 1984; Smith *et al.*, 2006), and clinicians should be aware of its varied non-specific presentations.

A key feature of this patient's illness was the presentation of long-standing protein-losing enteropathy as the first manifestation of chronic DH. This is notable not only because protein-losing enteropathy is a most unusual form of GI histoplasmosis, but since GI tract disease is rarely symptomatic; even when present, symptoms are often non-specific (Kahi *et al.*, 2005). GI histoplasmosis is typically associated with inflammatory lesions or ulcers in the intestine (Cappell *et al.*, 1988), which were absent in our patient. In HIV-positive individuals, diarrhoea, fever and abdominal pain are common and large-bowel disease is characteristic (60 % of cases) (Kauffman, 2007; Suh *et al.*, 2001). In contrast, small-bowel disease with protein-losing enteropathy or malabsorption are rare complications of GI histoplasmosis (Bank *et al.*, 1965; Orchard *et al.*, 1979; this study). In support of GI histoplasmosis as the cause of the enteropathy in this case is the symptomatic improvement and biopsy-proven reversal of abnormal villous morphology following antifungal treatment. The persistence of hypogammaglobulinaemia is probably due to incomplete reversal of the longstanding pathological process, although persistence of infection is not excluded as *Histoplasma* organisms were still seen in the repeat jejunal biopsy samples.

Given the propensity for both *Histoplasma* and *Nocardia* to cause disseminated infection, investigation of other anatomical sites for disease is essential for effective patient management. In our patient, the pulmonary lesions could be due to either histoplasmosis or nocardiosis. A respiratory specimen, which was not obtained, may have identified the causative infective agent. Pulmonary nocardiosis though seems more likely, due to the lack of calcification in the lung nodules and the propensity for pulmonary 'histoplasmomas' to persist despite treatment (Kauffman, 2007; Goodwin & Snell, 1969). Despite negative microbiological and histopathological results from adrenal biopsy, adrenal involvement is common in DH, and the CT appearances of the adrenal glands in this patient (bilateral organ enlargement, hypoattenuation with rim enhancement and low-density foci of necrosis) support the diagnosis of adrenal histoplasmosis (Grover *et al.*, 2005). In contrast, adrenal nocardiosis is rare and typical CT scan findings comprise contrast-enhanced heterogeneous appearances with internal septations (Midiri *et al.*, 1998).

The development of two unusual opportunistic infections in this patient strongly suggested a cellular immunodeficiency, although thorough investigation failed to define any known genetic or functional defect. His CD4 count was only slightly below the lower limit of the normal range, and since the CD4 proportion of lymphocytes was always normal, this simply reflected his persistent lymphopenia, itself most likely due to lymphangiectasia. In the absence of a family history, it is difficult to further investigate this and other similar cases of undefined cellular immunodeficiency.

Of interest, we were unable to identify the pathogenic *Nocardia* organism to species level. It was not surprising that phenotypic-based methods including antimicrobial susceptibility profiles were not able to identify the organism since these methods are insensitive (Brown-

Elliott *et al.*, 2006). 16S rRNA gene sequencing is the current 'gold standard' method for species identification of *Nocardia*; however, it may be unable to distinguish between certain closely related *Nocardia* species due to insufficient inter-species polymorphisms within the 16S rDNA sequences (Roth *et al.*, 2003; Brown-Elliott *et al.*, 2006), as was apparent in the isolate from this patient. Analyses of alternative *Nocardia* genes were not examined in this case. Nonetheless, the patient was successfully managed with antimicrobial agents known to be effective against many *Nocardia* species.

Finally, we postulate that the patient's caving resulted in exposure to a large inoculum of *Histoplasma*, although the lack of respiratory illness seems unusual. His occupational exposure has likely provided the source for the *Nocardia* infection.

In summary, this case highlights a rare manifestation of an uncommon complication of histoplasmosis in the context of simultaneous occurrence of nocardiosis. Symptomatic GI histoplasmosis is rare and clinicians should be aware of its varied presentations. Although no specific immune deficit was uncovered in our patient, the presence of two unusual opportunistic infections should prompt investigation of underlying immune deficiency.

Acknowledgements

The authors thank Mrs Ok-Cha Lee for performing the culture-based identification studies of the *Histoplasma* and *Nocardia* isolate.

References

Antachopoulos, C., Walsh, T. J. & Roilides, E. (2007). Fungal infections in primary immunodeficiencies. *Eur J Pediatr* **166**, 1099–1117.

Bank, S., Trey, C., Gans, I., Marks, I. N. & Groll, A. (1965). Histoplasmosis of the small bowel with "giant" intestinal villi and secondary protein-losing enteropathy. *Am J Med* **39**, 492–501.

Brown-Elliott, B. A., Brown, J. M., Conville, P. S. & Wallace, R. J., Jr (2006). Clinical and laboratory features of the *Nocardia* spp. based on current molecular taxonomy. *Clin Microbiol Rev* **19**, 259–282.

Cappell, M. S., Mandell, W., Grimes, M. M. & Neu, H. C. (1988). Gastrointestinal histoplasmosis. *Dig Dis Sci* **33**, 353–360.

Georghiou, P. R. & Blacklock, Z. M. (1992). Infection with *Nocardia* species in Queensland. A review of 102 isolates. *Med J Aust* **156**, 692–697.

Goodwin, R. A., Jr & Snell, J. D., Jr (1969). The enlarging histoplasmoma: concept of a tumor-like phenomenon encompassing the tuberculoma and coccidioidoma. *Am Rev Respir Dis* **100**, 1–12.

Grover, S. B., Midha, N., Gupta, M., Sharma, U. & Talib, V. H. (2005). Imaging spectrum in disseminated histoplasmosis: case report and brief review. *Australas Radiol* **49**, 175–178.

Hunt, P. J., Harden, T. J., Hibbins, M., Pritchard, R. C., Muir, D. B. & Gardner, F. J. (1984). *Histoplasma capsulatum*. Isolation from an Australian cave environment and from a patient. *Med J Aust* **141**, 280–283.

Kahi, C. J., Wheat, L. J., Allen, S. D. & Sarosi, G. A. (2005). Gastrointestinal histoplasmosis. *Am J Gastroenterol* **100**, 220–231.

Kauffman, C. A. (2007). Histoplasmosis: a clinical and laboratory update. *Clin Microbiol Rev* **20**, 115–132.

Lau, A., Chen, S., Sorrell, T., Carter, D., Malik, R., Martin, P. & Halliday, C. (2007). Development and clinical application of a panfungal PCR assay to detect and identify fungal DNA in tissue specimens. *J Clin Microbiol* **45**, 380–385.

Midiri, M., Finazzo, M., Bartolotta, T. V. & Maria, M. D. (1998). Nocardial adrenal abscess: CT and MR findings. *Eur Radiol* **8**, 466–468.

Orchard, J. L., Luparello, F. & Brunskill, D. (1979). Malabsorption syndrome occurring in the course of disseminated histoplasmosis: case report and review of gastrointestinal histoplasmosis. *Am J Med* **66**, 331–336.

Roth, A., Andrees, S., Kroppenstedt, R. M., Harmsen, D. & Mauch, H. (2003). Phylogeny of the genus *Nocardia* based on reassessed 16S rRNA gene sequences reveals underspeciation and division of strains classified as *Nocardia asteroides* into three established species and two unnamed taxons. *J Clin Microbiol* **41**, 851–856.

Smith, R., Lee, A., Gottlieb, T., Eckstein, R. & Meng, L. (2006). Another case of histoplasmosis in a non-endemic area. *Pathology* **38**, 378–380.

Suh, K. N., Anekthananon, T. & Mauriuz, P. R. (2001). Gastrointestinal histoplasmosis in patients with AIDS: case report and review. *Clin Infect Dis* **32**, 483–491.

Wheat, L. J., Connolly-Stringfield, P. A., Baker, R. L., Curfman, M. F., Eads, M. E., Israel, K. S., Norris, S. A., Webb, D. H. & Zeckel, M. L. (1990). Disseminated histoplasmosis in the acquired immune deficiency syndrome: clinical findings, diagnosis and treatment, and review of the literature. *Medicine* **69**, 361–374.

Wheat, L. J., Freifeld, A. G., Kleiman, M. B., Baddley, J. W., McKinsey, D. S., Loyd, J. E. & Kauffman, C. A. (2007). Clinical practice guidelines for the management of patients with histoplasmosis: 2007 update by the Infectious Diseases Society of America. *Clin Infect Dis* **45**, 807–825.

Zerbe, C. S. & Holland, S. M. (2005). Disseminated histoplasmosis in persons with interferon-γ receptor 1 deficiency. *Clin Infect Dis* **41**, e38–e41.