

## Case Report

# Treatment of chronic pulmonary blastomycosis with caspofungin

Joëlle Mardini,<sup>1</sup> Bich Nguyen,<sup>2</sup> Marc Ghannoum,<sup>3</sup> Christian Couture<sup>4</sup> and Valéry Lavergne<sup>5</sup>

### Correspondence

Valéry Lavergne  
valerylavergne@gmail.com

<sup>1</sup>University of Montréal, Montréal, Canada

<sup>2</sup>Department of Pneumology, Sacré-Coeur Hospital, Montréal, Canada

<sup>3</sup>Department of Medicine, Verdun Hospital, Montréal, Canada

<sup>4</sup>Department of Anatomic Pathology and Cytology, Institut Universitaire de Cardiologie et de Pneumologie de Québec (Hôpital Laval), Québec, Canada

<sup>5</sup>Department of Medical Microbiology and Infectious Diseases, Sacré-Coeur Hospital, Montréal, Canada

Current practice guidelines recommend that pulmonary blastomycosis be treated with antifungal agents such as amphotericin B and itraconazole. Echinocandins are not recommended because of poor *in vitro* activity against *Blastomyces dermatitidis* and lack of supporting clinical data. We report a case of chronic pulmonary blastomycosis treated successfully with caspofungin.

Received 13 July 2011

Accepted 12 August 2011

## Case report

A 32-year-old male with no prior history of disease and working in construction presented with an insidious onset of right thoracic pain in November 2008. He was living in proximity of the St. Lawrence River, and had recently been exposed to a flooded soil environment. He did not take any medication and had a 42 pack-years smoking history. His chest pain was later followed by haemoptysis and exacerbation of a chronic cough. The patient denied any dyspnoea or expectorations and did not report any constitutional symptoms except for occasional nocturnal diaphoresis. The systems inquiry and physical examination were otherwise unremarkable.

Laboratory testing revealed a white blood cell count of  $11.2 \times 10^9$  cells  $l^{-1}$  and an erythrocyte sedimentation rate slightly elevated at 24 mm  $h^{-1}$ . Biochemistry results were in the normal range. A chest X-ray on admission showed discrete opacities in the right paratracheal area. HIV, p-ANCA and c-ANCA testing were negative. In December 2008, a thoracic computed tomography (CT) scan demonstrated a right upper lobe parenchymal consolidation of 47 × 61 mm with occlusion of the left superior lobe bronchus. Bronchocentric nodular opacities and infracentimetric mediastinal lymph nodes were also visualized (Fig. 1a). Bronchoscopy confirmed the presence of an obstructive polypoid mass in the left superior bronchus. An endobronchial biopsy revealed non-necrotizing granulomatous

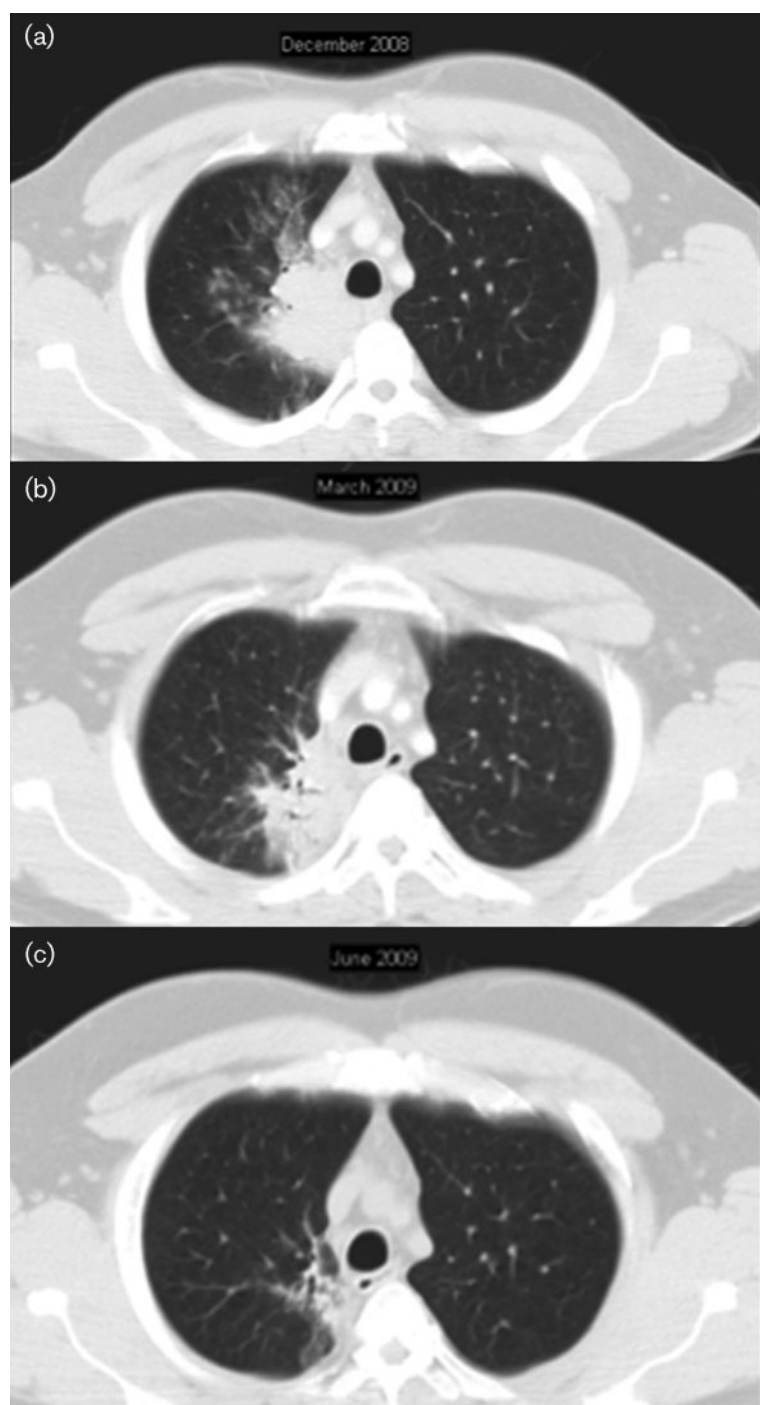
inflammation with several multinucleated giant cells without micro-organisms, neoplasm or vasculitis.

In February 2009, further investigation was undertaken because the pulmonary mass had remained identical on control CT scan. A transthoracic needle biopsy demonstrated a fibroinflammatory reaction with multinucleated giant cells and a suppurative infiltrate containing a few 10 µm spherical micro-organisms with a thick wall and broad-based budding consistent with *Blastomyces dermatitidis* (Fig. 2). Despite negative cultures, histopathology was sufficient to confirm definite diagnosis of blastomycosis (De Pauw *et al.*, 2008).

In March 2009, the working diagnosis was chronic pulmonary blastomycosis in an immunocompetent host without evidence of dissemination. Because of the absence of spontaneous resolution at least 3 months after presentation, we decided to initiate antifungal therapy. The patient first received amphotericin B deoxycholate (Fungizone; Bristol-Myers Squibb) for 4 days but developed acute renal failure (serum creatinine rapidly increased from 70 to 225 µmol  $l^{-1}$ ). Treatment was switched to liposomal amphotericin B (AmBisome; Astellas Pharma) for 5 days with no improvement of renal function. The total administered cumulative dose of amphotericin B deoxycholate equivalent was 0.55 g. Follow-up thoracic CT scan at that time showed a 30% improvement in the volume of the lesion (Fig. 1b).

Itraconazole (Sporanox; Janssen-Ortho) was later given but the patient developed a severe allergic rash after 4 days of administration. Because of the severity of the reaction, no

Abbreviation: CT, computed tomography.



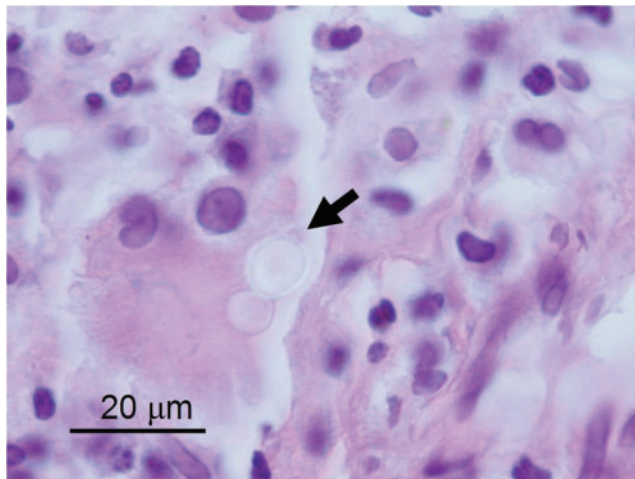
**Fig. 1.** Thoracic CT follow-up: (a) prior to treatment showing right upper lobe parenchymal consolidation with satellite nodular opacities (December 2008); (b) after amphotericin B therapy showing a 30% improvement (March 2009); (c) after completion of caspofungin treatment showing absence of active disease (June 2009).

attempt was made to rechallenge the patient with another azole.

After 6 weeks of caspofungin (Cancidas; Merck) (70 mg i.v. the first day followed by 50 mg i.v. daily thereafter), the control CT scan did not show evidence of active disease, solely residual scarring tissue (Fig. 1c). Although longer therapy was recommended, the patient decided to cease treatment because of PICC-line inconvenience. No recurrence occurred during the 16 months follow-up and CT images in September 2010 did not show disease reactivation.

## Discussion

*B. dermatitidis* is a dimorphic fungus endemic to regions bordering the Great Lakes as well as the St. Lawrence, Mississippi and Ohio Rivers. The mycelial form is recovered in warm moist soil, rich in organic debris. Disruption of the soil is probably necessary for spore aerosolization and dissemination. After inhalation and incubation at body temperature, the spores will transform into the pathogenic yeast form and cause a local pyogranulomatous reaction (Kralt *et al.*, 2009).



**Fig. 2.** Histology from transthoracic needle core biopsy: spherical 10 µm-wide micro-organism with a thick wall and broad-based budding consistent with *Blastomyces dermatitidis* (haematoxylin and eosin stain).

Half of the patients exposed to *B. dermatitidis* will develop symptoms. Acute blastomycosis can present itself as a flu-like illness, pneumonia or occasionally as a rapidly progressive respiratory distress syndrome. Some physicians prefer to manage mild cases of acute pulmonary blastomycosis conservatively without antifungal therapy and monitor these patients closely for years, considering the disease typically resolves spontaneously in its acute phase (Sarosi *et al.*, 1986). Nevertheless, there have been well-documented cases of acute exacerbations, development of chronic disease, relapse or haematogenous dissemination to various organs if left untreated (Bradsher, 1996). Furthermore, it is impossible to predict which patients will spontaneously recover, which explains why many physicians decide to treat these cases (Saccante & Woods, 2010).

Chronic pulmonary blastomycosis presents as an indolent respiratory illness with systemic symptoms persisting over a 2–6-month period, which can mimic tuberculosis or cancer. Spontaneous resolution of chronic blastomycosis is considered uncommon (Bradsher & Bariola, 2011) despite scattered evidence suggesting the contrary (Sarosi *et al.*, 1986). If left untreated, chronic blastomycosis is associated with significant mortality. For these reasons, some authors recommend that all patients with chronic pulmonary blastomycosis receive antifungal therapy (Bradsher & Bariola, 2011; Saccante & Woods, 2010). In our patient, there were no signs of improvement after at least 3 months of disease, hence our decision to begin treatment.

For mild to moderate cases of non-disseminated pulmonary blastomycosis in immunocompetent patients, the 2008 updated clinical practice guidelines recommend a 6–12-month course of oral itraconazole. For more severe cases, a 1–2-week course of intravenous lipid amphotericin B prior

to itraconazole is recommended (Chapman *et al.*, 2008). Although broad-spectrum azoles, like voriconazole or posaconazole, could also be used in this context (Bariola *et al.*, 2010; Sugar & Liu, 1996, 2001), there are conflictual data on their cross-reactivity with itraconazole [Chen *et al.*, 2009; Janssen, 2011; Pinto & Chan, 2009; Thomson Reuters MICROMEDEX (<http://www.thomsonhc.com>), last accessed 7 August 2011]. Given the severity of the observed allergic reaction, it seemed justified at the time to avoid this drug class, although only future studies could determine their real safety in the context of an itraconazole allergy. Current guidelines also stipulate that echinocandins (caspofungin, micafungin and anidulafungin) should not be used in the treatment of blastomycosis. In the absence of clinical data, this recommendation was extrapolated from two *in vitro* studies that showed ‘poor to intermediate *in vitro* activity against *B. dermatitidis*’ (Espinel-Ingroff, 1998; Nakai *et al.*, 2003).

There are reasons, however, to question the validity of this statement. Firstly, since *B. dermatitidis* is a dimorphic fungus, it is unclear which form (mycelium or yeast) should be studied, although the latter is considered pathogenic. As noted by Nakai *et al.* (2003), both forms have markedly different MICs, the yeast being generally less susceptible. Secondly, susceptibility testing for blastomycosis is not standardized and is often derived from Clinical and Laboratory Standards Institute standards for yeasts and filamentous fungi; however, every individual pathogen must undergo a rigorous process to ensure that the method is reproducible. This can perhaps explain the large discrepancies in the MICs for *B. dermatitidis* mycelia in the two aforementioned studies (MIC range of micafungin varying from 0.008–0.03 to 0.5–8 µg ml<sup>-1</sup>) (Espinel-Ingroff, 1998; Nakai *et al.*, 2003). Thirdly, echinocandin susceptibility testing itself is incompletely validated for most fungi (including the most common ones). For example, in *Aspergillus* species, the absence of *in vitro*–*in vivo* correlation for caspofungin prevents minimal effective concentration interpretative breakpoints from being established (CLSI, 2008a). For *Candida* species, although data suggest that susceptibility to caspofungin can be predicted when isolates have MICs ≤ 2 µg ml<sup>-1</sup>, no breakpoint value exists to determine a resistant category (CLSI, 2008b). It would have been interesting to assess these methods in our patient; unfortunately, cultures were negative. Finally, extrapolation of *in vitro* studies claiming resistance necessitates clinical correlation to predict outcome.

These points can be better illustrated by the following example. In one study, 25 clinical strains of *Coccidioides immitis* showed poor *in vitro* susceptibility to caspofungin (mycelial form MIC at 48 h ranging from 8 to 64 µg ml<sup>-1</sup>). Yet, when two of these strains were injected in an experimental murine model, caspofungin was still found to be effective clinically (González *et al.*, 2001). Similarly, caspofungin was shown efficacious in treating a disseminated coccidioidomycosis infection in a renal transplant recipient intolerant to standard therapy (Antony, 2004). This

evidence alone was sufficient to consider caspofungin of possible benefit in coccidioidomycosis guidelines (Galgiani *et al.*, 2005). It is unclear whether the same inference can be made about caspofungin for blastomycosis.

Our patient's radiological lesions markedly improved with caspofungin therapy without evidence of later recurrence. We cannot completely exclude that there would have been spontaneous resolution if the patient had been left untreated but this is improbable considering the absence of radiological change during 3 months prior to treatment. Furthermore, it is also possible that amphotericin therapy may have triggered the documented improvement, although this appears unlikely given that only one-quarter of the usual recommended 2 g had been given (Chapman *et al.*, 2008), with marginal radiological changes 1 week after amphotericin cessation.

In conclusion, to the knowledge of the authors, this is the first reported case of successful treatment with caspofungin in an immunocompetent patient with chronic pulmonary blastomycosis. Although we do not suggest caspofungin replace standard therapy for blastomycosis, it should not be discarded based solely on *in vitro* data. In patients intolerant to azoles and amphotericin, caspofungin could be considered a potentially effective alternative, but this should be strengthened by future studies addressing *in vitro*–*in vivo* correlation.

## Acknowledgements

This work was partially supported by Merck & Co.

## References

- Antony, S. (2004). Use of the echinocandins (caspofungin) in the treatment of disseminated coccidioidomycosis in a renal transplant recipient. *Clin Infect Dis* **39**, 879–880.
- Bariola, J. R., Perry, P., Pappas, P. G., Proia, L., Shealey, W., Wright, P. W., Sizemore, J. M., Robinson, M. & Bradsher, R. W., Jr (2010). Blastomycosis of the central nervous system: a multicenter review of diagnosis and treatment in the modern era. *Clin Infect Dis* **50**, 797–804.
- Bradsher, R. W. (1996). Histoplasmosis and blastomycosis. *Clin Infect Dis* **22** (Suppl. 2), S102–S111.
- Bradsher, R. W. & Bariola, J. R. (2011). Blastomycosis. In *Essentials of Clinical Mycology*, 2nd edn, pp. 337–348. Edited by C. A. Kauffman, P. G. Pappas, J. D. Sobel & W. E. Dismukes. New York: Springer.
- Chapman, S. W., Dismukes, W. E., Proia, L. A., Bradsher, R. W., Pappas, P. G., Threlkeld, M. G. & Kauffman, C. A. (2008). Clinical practice guidelines for the management of blastomycosis: 2008 update by the Infectious Diseases Society of America. *Clin Infect Dis* **46**, 1801–1812.
- Chen, J., Song, X., Yang, P. & Wang, J. (2009). Appearance of anaphylactic shock after long-term intravenous itraconazole treatment. *Ann Pharmacother* **43**, 537–541.
- CLSI (2008a). *Reference Method for Broth Dilution Antifungal Susceptibility Testing of Filamentous Fungi*; Approved Standard, 2nd edn. M38-A2. Wayne, PA: Clinical and Laboratory Standards Institute.
- CLSI (2008b). *Reference Method for Broth Dilution Antifungal Susceptibility Testing of Yeasts*; Approved Standard, 3rd edn. M27-A3. Wayne, PA: Clinical and Laboratory Standards Institute.
- De Pauw, B., Walsh, T. J., Donnelly, J. P., Stevens, D. A., Edwards, J. E., Calandra, T., Pappas, P. G., Maertens, J., Lortholary, O. & other authors (2008). Revised definitions of invasive fungal disease from the European Organization for Research and Treatment of Cancer/Invasive Fungal Infections Cooperative Group and the National Institute of Allergy and Infectious Diseases Mycoses Study Group (EORTC/MSG) Consensus Group. *Clin Infect Dis* **46**, 1813–1821.
- Espinel-Ingroff, A. (1998). Comparison of *in vitro* activities of the new triazole SCH56592 and the echinocandins MK-0991 (L-743,872) and LY303366 against opportunistic filamentous and dimorphic fungi and yeasts. *J Clin Microbiol* **36**, 2950–2956.
- Galgiani, J. N., Ampel, N. M., Blair, J. E., Catanzaro, A., Johnson, R. H., Stevens, D. A., Williams, P. L. on behalf of the Infectious Diseases Society of America (2005). Coccidioidomycosis. *Clin Infect Dis* **41**, 1217–1223.
- González, G. M., Tijerina, R., Najvar, L. K., Bocanegra, R., Luther, M., Rinaldi, M. G. & Graybill, J. R. (2001). Correlation between antifungal susceptibilities of *Coccidioides immitis* *in vitro* and antifungal treatment with caspofungin in a mouse model. *Antimicrob Agents Chemother* **45**, 1854–1859.
- Janssen (2011). *Product Monograph – Sporanox*. Toronto: Janssen Inc.
- Kralt, D., Light, B., Cheang, M., MacNair, T., Wiebe, L., Limerick, B., Sarsfield, P., Hammond, G., MacDonald, K. & other authors (2009). Clinical characteristics and outcomes in patients with pulmonary blastomycosis. *Mycopathologia* **167**, 115–124.
- Nakai, T., Uno, J., Ikeda, F., Tawara, S., Nishimura, K. & Miyaji, M. (2003). *In vitro* antifungal activity of micafungin (FK463) against dimorphic fungi: comparison of yeast-like and mycelial forms. *Antimicrob Agents Chemother* **47**, 1376–1381.
- Pinto, A. & Chan, R. C. (2009). Lack of allergic cross-reactivity between fluconazole and voriconazole. *Antimicrob Agents Chemother* **53**, 1715–1716.
- Saccante, M. & Woods, G. L. (2010). Clinical and laboratory update on blastomycosis. *Clin Microbiol Rev* **23**, 367–381.
- Sarosi, G. A., Davies, S. F. & Phillips, J. R. (1986). Self-limited blastomycosis: a report of 39 cases. *Semin Respir Infect* **1**, 40–44.
- Sugar, A. M. & Liu, X. P. (1996). *In vitro* and *in vivo* activities of SCH 56592 against *Blastomyces dermatitidis*. *Antimicrob Agents Chemother* **40**, 1314–1316.
- Sugar, A. M. & Liu, X. P. (2001). Efficacy of voriconazole in treatment of murine pulmonary blastomycosis. *Antimicrob Agents Chemother* **45**, 601–604.