

Case Report

Subcutaneous abscess formation in the upper extremity caused by toxigenic *Corynebacterium ulcerans*

Takaaki Urakawa,¹ Junji Seto,² Akihiko Yamamoto,³ Tomoko Nakajima⁴ and Shinichi Goto¹

Correspondence

Takaaki Urakawa
takaaki-u@mwe.biglobe.ne.jp

¹Department of Orthopedic Surgery, Tsuruoka Municipal Shonai Hospital, 4-20 Izumi-machi, Tsuruoka-shi, Yamagata 997-8515, Japan

²Department of Microbiology, Yamagata Prefectural Institute of Public Health, 1-6-6 Toka-machi, Yamagata 990-0031, Japan

³Department of Bacteriology II, National Institute of Infectious Diseases, 4-7-1 Gakuen Musashimurayama-shi, Tokyo 208-0011, Japan

⁴Central Inspection Department, Tsuruoka Municipal Shonai Hospital, 4-20 Izumi-machi, Tsuruoka-shi, Yamagata 997-8515, Japan

Received 28 August 2012
Accepted 2 December 2012

Corynebacterium ulcerans is attracting attention as an emerging zoonosis that causes lymphadenitis, dermatitis and respiratory infections. We report here what appears to be the first case of subcutaneous abscess formation in the upper extremity due to toxigenic *C. ulcerans* in Japan. Awareness of the fact that *C. ulcerans* can cause a subcutaneous, elastic-hard, less-mobile mass with heat, redness and pain in the extremities is important for differential diagnosis.

Introduction

Corynebacterium ulcerans is known as an emerging zoonosis that causes cutaneous infection, sinusitis, tonsillitis, pharyngitis, pneumonia and peritonitis (Dias *et al.*, 2011). However, to the best of our knowledge, *C. ulcerans* has not been reported to cause subcutaneous abscess in the extremities. Therefore, clinicians encountering a subcutaneous mass in the extremities are unlikely to consider subcutaneous abscesses due to *C. ulcerans* as a differential diagnosis. This could lead to a delay in diagnosis and treatment, and in the worst scenario, it may result in a fatal diphtheria-like disease (Mattos-Guaraldi *et al.*, 2008; Putong *et al.*, 2011).

Here, we report the diagnosis and treatment of a patient with a subcutaneous abscess in the upper extremity due to *C. ulcerans* and discuss the clinical characteristics useful for differential diagnosis.

Case report

In December 2011, a 37-year-old Japanese woman was referred to Tsuruoka Municipal Shonai Hospital, in Tsuruoka, Japan, with a painful mass in her right elbow. The patient had no cardiac symptoms. Her past medical history was unremarkable. Three days before the current hospital visit, she experienced swelling and itching on the

medial side of her right elbow. Within a few days, a hot, red, painful mass rapidly formed subcutaneously.

Physical examination revealed redness and local heat on the surface of the skin over the mass. The mass was approximately 4 cm in size, elastic hard and less mobile, and caused pain and tenderness. No radiating pain was produced on tapping on the mass (Tinel's sign). Laboratory tests revealed an increase in C-reactive protein levels (2.3 mg dl⁻¹) and a white blood cell count in the normal range (7500 mm⁻³). Radiography did not reveal calcification within the lesion. On magnetic resonance imaging, a subcutaneous soft tissue mass (27 × 22 × 26 mm in size) was observed on the medial side of her elbow; it exhibited iso-signal intensity on T1-weighted images (Fig. 1a) and inhomogeneous high-signal intensity on T2-weighted images (Fig. 1b). Following intravenous administration of gadopentetate dimeglumine, ring enhancement was seen on T1-weighted images (Fig. 1c).

Fine-needle aspiration biopsy was performed. No pus was aspirated, but small fragments of tissue were obtained. The tissue fragments were sent for pathological analysis and microbiological diagnosis. Histopathological examination showed no malignancy, but neutrophils and histiocytes were present in the specimen. Bacterial cultures were negative under aerobic conditions.

In January 2012, the patient underwent surgery to enable a definite diagnosis and alleviate the pain. By this time, the

The GenBank/EMBL/DDJB accession number for the *ropB* sequence of *C. ulcerans* 469-Yamagata-2011 is AB751261.

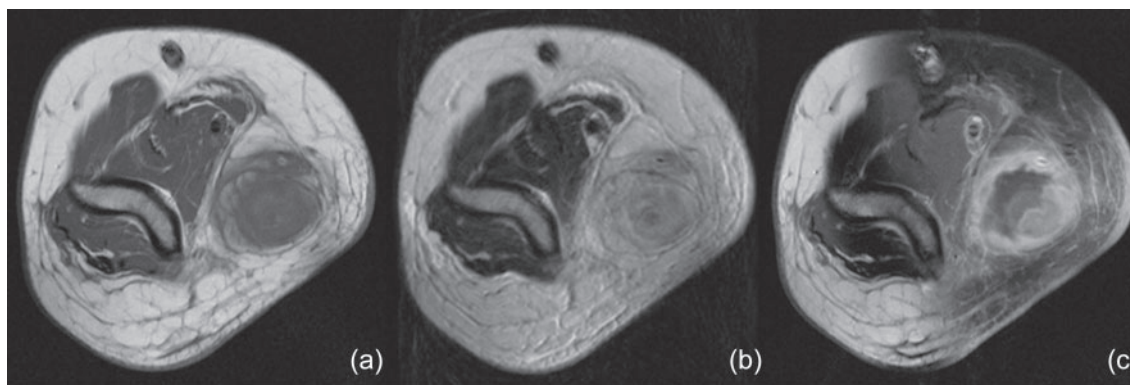


Fig. 1. Magnetic resonance imaging showing a subcutaneous soft tissue mass (27×22×26 mm in size) on the medial side of the patient's elbow. The mass demonstrates iso-signal intensity on the T1-weighted image (a), inhomogeneous high-signal intensity on the T2-weighted image (b), and ring enhancement on the gadolinium-enhanced T1-weighted image (c).

patient had developed numbness in the right long, ring and little fingers. A skin incision was made longitudinally along the mass under axillary brachial plexus block. Inflammatory changes were observed in the subcutaneous fatty tissues; large feeding vessels were observed around the mass, and pus flowed from it on blunt dissection (Fig. 2a). There was no direct invasion or compression in the median or ulnar nerves. Finally, the mass was marginally resected (Fig. 2b, c) and a sample was sent for pathological examination and bacterial culture. After surgery, the patient was administered 100 mg oral cefditoren pivoxil three times daily for 3 days.

Histologically, the lesion was characterized as an abscess with necrosis, infiltrated with numerous inflammatory cells. The pus obtained at surgery exhibited the presence of Gram-positive short-rod organisms. Culture of the pus on sheep blood agar yielded Gram-positive, coryneform rods; the isolates were considered clinically significant. A search of the API Coryne database (SYSMEX bioMérieux)

identified the bacterium as *Corynebacterium pseudotuberculosis* (API code 0001304).

To confirm this biochemical identification, RNA polymerase b-subunit (*rpoB*) gene sequencing was performed (Khamis *et al.*, 2004). Sequence identities between the strain obtained at surgery (GenBank accession no. AB751261) and the *C. ulcerans* reference strain (GenBank accession no. CP002790) and *C. pseudotuberculosis* (GenBank accession no. CP003152) were 100 % and 92.8 %, respectively. The causative agent was therefore identified as *C. ulcerans*.

Diphtheria toxigenicity was tested using a modified Elek test (Engler *et al.*, 1997) and Vero cell cytotoxicity tests (Miyamura *et al.*, 1974), and the presence of the diphtheria toxin gene was tested by PCR. The PCR analysis, modified Elek test, Vero cell cytotoxicity tests results were all positive for isolated *C. ulcerans*. Antibiotic susceptibility tests were performed using the broth microdilution method on a Dry

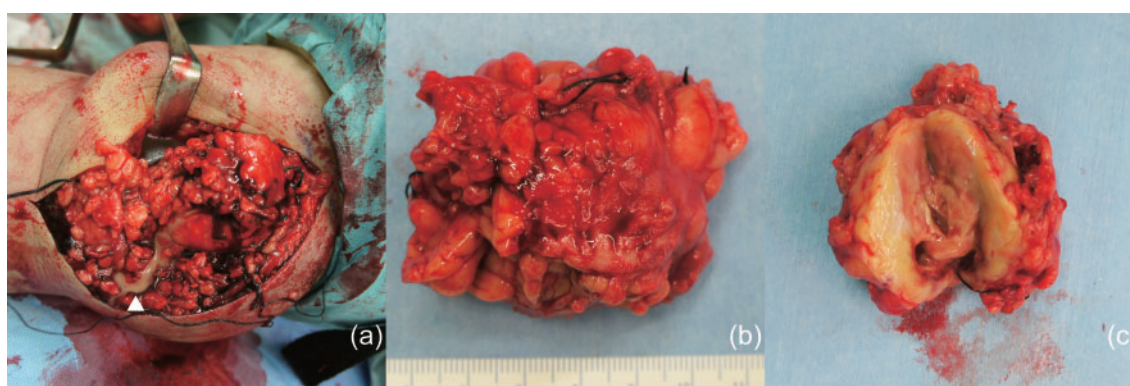


Fig. 2. At surgery, the mass was observed subcutaneously and inflammatory changes were found around it. In blunt dissection, pus flowed from the mass (arrowhead) (a). The resected mass (b) and its cut surface (c) are also shown.

Plate DP24 (Eiken Chemical Co.). The isolate was sensitive to benzylpenicillin, ampicillin, cefazolin, cefotiam, cefotaxime, cefaclor, cefditoren, flomoxef, imipenem, meropenem, erythromycin, minocycline, vancomycin and sulfamethoxazole–trimethoprim. The clindamycin minimum inhibitory concentration (M45-A) was 2 mg ml^{-1} , which was intermediate (CLSI, 2006).

One week after surgery, redness and swelling around the wound and forearm cellulitis were observed; irrigation and debridement under axillary brachial plexus block were performed. After this second surgery, the patient was treated with intravenous benzylpenicillin at 600 000 IU every 6 h for 3 weeks. Eleven days after the second surgery, 300 mg erythromycin four times a day was also administered for 6 weeks because the suction drain site was still wet and a skin ulcer had formed around it. Two months after the initial surgery, the wound had become completely dry and healed without sequelae, and the patient's finger numbness had also disappeared.

The patient's mother reported that she had received primary and booster diphtheria vaccinations. Her serum sample after the development of the disease was analysed by a retrospective toxin neutralization test using Vero cells (Miyamura *et al.*, 1974). On the seventh postoperative day, the serum antibody level to diphtheria toxin was 0.267 IU ml^{-1} (protection level $>0.1 \text{ IU ml}^{-1}$).

Risk assessments of human and animal contacts were performed. *C. ulcerans* was not isolated from throat swabs from the patient's two asymptomatic children or from the throat, ear and eye swabs from her six cats, which did not have any lesions. The patient's 11-year-old child had received the third booster vaccination 9 years before examination and had a 1.27 IU ml^{-1} serum antibody level to the diphtheria toxin. The patient's 12-year-old child had received the fourth booster vaccination 6 months before examination and had a serum antibody level of 6.02 IU ml^{-1} .

Using PFGE (De Zoysa *et al.*, 1995), the isolate was genetically compared with four isolates that were representatives of four groups into which a previous study classified the Japanese strains (Katsukawa *et al.*, 2012). The location cities from which the four *C. ulcerans* isolates had been reported were Chiba (strain 0102) (Hatanaka *et al.*, 2003; Komiya *et al.*, 2010), Okayama (strain 0509) (Asakura *et al.*, 2006), Oita (strain 0510) (Nureki *et al.*, 2007) and Kanagawa (strain 0607) (Hagiwara *et al.*, 2006). The PFGE results revealed that the genotype pattern of this patient's isolate showed 96% identity with that of the human isolate 0607 in Kanagawa.

Discussion

This case report describes what appears to be the first case of subcutaneous abscess formation in the upper extremity caused by toxigenic *C. ulcerans* in Japan. Diphtheria was historically one of the most common diseases caused by

toxigenic *C. diphtheriae*, but is now a rare occurrence in developed countries due to national vaccination programmes (Wagner *et al.*, 2010). However, many cases of diphtheria-like illness due to *C. ulcerans* have recently been reported in industrialized countries, including Japan (Dias *et al.*, 2011; Hatanaka *et al.*, 2003; Komiya *et al.*, 2010; Wagner *et al.*, 2010), and in urban areas in developing countries (Mattos-Guaraldi *et al.*, 2008). The classic and most severe presentation of diphtheria is a respiratory disease with tender swelling on both sides of the neck (bull neck) and a pseudomembrane in the pharynx mucosa, which obstructs the airway (Putong *et al.*, 2011). In addition to classic respiratory diphtheria, *C. ulcerans* is known to cause cutaneous infection, sinusitis, tonsillitis, pharyngitis, pneumonia and peritonitis (Dias *et al.*, 2011). Although cutaneous infection occurs in the extremities, to our knowledge, there are no reports describing subcutaneous abscess formation in the extremities due to *C. ulcerans*. Characteristics of this lesion were a subcutaneous, elastic-hard, less-mobile mass with heat, redness and pain. Although the differential diagnosis was sarcoma, the rapid formation of the mass strongly suggested an infectious lesion rather than a malignant tumour. Because human infection with this bacterium has been frequently reported (Bonmarin *et al.*, 2009; Katsukawa *et al.*, 2012), the incidence of subcutaneous lesions due to *C. ulcerans* may increase in the near future. Therefore, the fact that *C. ulcerans* can cause a subcutaneous painful mass in the extremities is important for differential diagnosis.

Human *C. ulcerans* infections are caused by ingestion of untreated milk (Bostock *et al.*, 1984) or close contact with animals (Hatanaka *et al.*, 2003; Komiya *et al.*, 2010; Tiwari *et al.*, 2008). Our patient had six pet cats; although these animals were examined, *C. ulcerans* strains were not detected. The patient had not consumed raw dairy products and had not been abroad; therefore, the source of infection could not be traced in this case. Further investigation of the transmission pathway of this bacterium is warranted.

The isolate was genetically compared with four isolates from Japanese human patients in an attempt to trace the transmission pathway. Although the isolate had 96% similarity to the strain from Kanagawa, the distance between Tsuruoka and Kanagawa was more than 300 km. Furthermore, the patient had not been to Kanagawa in the past several years. Therefore, there appeared to be no epidemiological association between this isolate and the strain from Kanagawa. As more cases are accumulated, genetic analysis results may have some association with those of epidemiological surveys.

Since there is no strong evidence that human-to-human transmission of *C. ulcerans* can occur, the isolation of infected patients is not mandatory by Japanese law. We examined whether human-to-human infection had occurred in the patient's family by analysing the antibody titres to the diphtheria toxin of the patient's two children.

In Japan, the fourth booster vaccination is administered to children at age 11. The patient's 11-year-old child had not received the fourth booster vaccination and had only received the third booster vaccination 9 years before examination. At this age (before receiving the fourth booster vaccination), children with serum antibody levels of >1.0 IU ml⁻¹ account for only 20% (IDSC, 2008). Therefore, there is a high possibility that an unapparent infection due to this toxigenic *C. ulcerans* had occurred in this child. However, the patient's 12-year-old child had already received the fourth booster vaccination. At this age (after receiving the fourth booster vaccination), children with serum antibody levels of >3.2 IU ml⁻¹ account for approximately 35% (IDSC, 2008). Therefore, it is difficult to speculate about whether this child's antibody titre level was due to a response to vaccination or to unapparent infection. Further studies should be conducted to determine whether *C. ulcerans* can cause human-to-human infection, and the possible necessity of isolating infected patients should also be considered.

It is known that diphtheria causes peripheral neuropathy (Solders *et al.*, 1989); demyelinating non-inflammatory neuropathy is usually seen within 8–12 weeks of throat infection. In the current patient, numbness in the innervation areas of the ulnar and median nerves was seen without motor weakness approximately 1 month after onset. The cause of this numbness was not explained by direct invasion or compression of the median or ulnar nerves. Another possibility is that the numbness of her fingers was related to the diphtheria toxin. The cause of her predominantly sensory impairment is unknown, although the median and ulnar nerves serve both sensory and motor functions. In addition to conventional nerve conduction tests, recent advances in noninvasive techniques such as neurography (Terumitsu *et al.*, 2011) and diffusion-weighted images (Ueki *et al.*, 2006; Urakawa *et al.*, 2011) will elucidate further detail regarding the aetiology of peripheral neuropathy in diphtheria.

Conclusions

We have presented, to our knowledge, the first case of subcutaneous abscess formation in the upper extremity due to toxigenic *C. ulcerans* in Japan. The incidence of *C. ulcerans* infection is expected to increase in the near future; therefore, it is important to bear in mind that subcutaneous lesions caused by this bacterium may be found in the extremities.

Acknowledgements

This work was supported in part by Health and Labour Sciences Research Grants (Research on Emerging and Re-emerging Infectious Diseases and Research on Pharmaceutical and Medical Safety, H19-Shinkou-Ippan-009). We gratefully acknowledge the assistance and advice from Dr A. Ogose, Dr T. Ariizumi, Dr S. Kawachi, Dr T. Mizouchi, Dr T. Yamagishi and Dr M. Fukase.

References

- Asakura, S., Katayama, N., Hara, Y., Sunami, K., Ohgami, T., Takeda, Y., Mimura, S., Yamatori, I., Ohkusu, K. & other authors (2006). [A case of cervico-lymphadenitis due to *Corynebacterium ulcerans*, 2005 – Okayama]. *Infect Agents Surveill Rep* 27, 124–125 (in Japanese).
- Bonmarin, I., Guiso, N., Le Flèche-Matéos, A., Patey, O., Patrick, A. D. & Levy-Bruhl, D. (2009). Diphtheria: a zoonotic disease in France? *Vaccine* 27, 4196–4200.
- Bostock, A. D., Gilbert, F. R., Lewis, D. & Smith, D. C. (1984). *Corynebacterium ulcerans* infection associated with untreated milk. *J Infect* 9, 286–288.
- CLSI (2006). *Methods for Antimicrobial Dilution and Disk Susceptibility Testing of Infrequently Isolated or Fastidious Bacteria*; Approved Guideline, CLSI document M45-A. Wayne, PA: Clinical and Laboratory Standards Institute.
- De Zoysa, A., Efstratiou, A., George, R. C., Jahkola, M., Vuopio-Varkila, J., Deshevoi, S., Tseneva, G. Y. & Rikushin, Y. (1995). Molecular epidemiology of *Corynebacterium diphtheriae* from north-western Russia and surrounding countries studied by using ribotyping and pulsed-field gel electrophoresis. *J Clin Microbiol* 33, 1080–1083.
- Dias, A. A., Santos, L. S., Sabbadini, P. S., Santos, C. S., Silva Junior, F. C., Napoleão, F., Nagao, P. E., Villas-Bôas, M. H., Hirata Junior, R. & Guaraldi, A. L. (2011). [*Corynebacterium ulcerans* diphtheria: an emerging zoonosis in Brazil and worldwide]. *Rev Saude Publica* 45, 1176–1191 (in Portuguese).
- Engler, K. H., Glushkevich, T., Mazurova, I. K., George, R. C. & Efstratiou, A. (1997). A modified Elek test for detection of toxigenic corynebacteria in the diagnostic laboratory. *J Clin Microbiol* 35, 495–498.
- Hagiwara, N., Horike, S., Kasahara, S., Suganuma, T., Aizawa, T., Nakamura, K., Nakanishi, M., Yatsuhashi, R., Okazaki, N. & other authors (2006). [A diphtheria-like case due to *Corynebacterium ulcerans*, July 2006 – Kanagawa]. *Infect Agents Surveill Rep* 27, 334–335 (in Japanese).
- Hatanaka, A., Tsunoda, A., Okamoto, M., Ooe, K., Nakamura, A., Miyakoshi, M., Komiya, T. & Takahashi, M. (2003). *Corynebacterium ulcerans* diphtheria in Japan. *Emerg Infect Dis* 9, 752–753.
- IDSC (2008). Diphtheria. In *National Epidemiological Surveillance of Vaccine-Preventable Diseases*, pp. 201–216. Tokyo: NIID.
- Katsukawa, C., Komiya, T., Yamagishi, H., Ishii, A., Nishino, S., Nagahama, S., Iwaki, M., Yamamoto, A. & Takahashi, M. (2012). Prevalence of *Corynebacterium ulcerans* in dogs in Osaka, Japan. *J Med Microbiol* 61, 266–273.
- Khamis, A., Raoult, D. & La Scola, B. (2004). *rpoB* gene sequencing for identification of *Corynebacterium* species. *J Clin Microbiol* 42, 3925–3931.
- Komiya, T., Seto, Y., De Zoysa, A., Iwaki, M., Hatanaka, A., Tsunoda, A., Arakawa, Y., Kozaki, S. & Takahashi, M. (2010). Two Japanese *Corynebacterium ulcerans* isolates from the same hospital: ribotype, toxigenicity and serum antitoxin titre. *J Med Microbiol* 59, 1497–1504.
- Mattos-Guaraldi, A. L., Sampaio, J. L., Santos, C. S., Pimenta, F. P., Pereira, G. A., Pacheco, L. G., Miyoshi, A., Azevedo, V., Moreira, L. O. & other authors (2008). First detection of *Corynebacterium ulcerans* producing a diphtheria-like toxin in a case of human with pulmonary infection in the Rio de Janeiro metropolitan area, Brazil. *Mem Inst Oswaldo Cruz* 103, 396–400.
- Miyamura, K., Tajiri, E., Ito, A., Murata, R. & Kono, R. (1974). Micro cell culture method for determination of diphtheria toxin and antitoxin titres using VERO cells. II. Comparison with the rabbit skin method and practical application for seroepidemiological studies. *J Biol Stand* 2, 203–209.

- Nureki, S.-i., Miyazaki, E., Matsuno, O., Takenaka, R., Ando, M., Kumamoto, T., Nakano, T., Ohkusu, K. & Ezaki, T. (2007). *Corynebacterium ulcerans* infection of the lung mimicking the histology of Churg–Strauss syndrome. *Chest* **131**, 1237–1239.
- Putong, N., Agustin, G., Pasubillo, M., Miyagi, K. & Dimaano, E. M. (2011). Diphtheria-like illness due to *Corynebacterium ulcerans* infection. *Trop Med Health* **39**, 1–2.
- Solders, G., Nennesmo, I. & Persson, A. (1989). Diphtheritic neuropathy, an analysis based on muscle and nerve biopsy and repeated neurophysiological and autonomic function tests. *J Neurol Neurosurg Psychiatry* **52**, 876–880.
- Terumitsu, M., Seo, K., Matsuzawa, H., Yamazaki, M., Kwee, I. L. & Nakada, T. (2011). Morphologic evaluation of the inferior alveolar nerve in patients with sensory disorders by high-resolution 3D volume rendering magnetic resonance neurography on a 3.0-T system. *Oral Surg Oral Med Oral Pathol Oral Radiol Endod* **111**, 95–102.
- Tiwari, T. S., Golaz, A., Yu, D. T., Ehresmann, K. R., Jones, T. F., Hill, H. E., Cassidy, P. K., Pawloski, L. C., Moran, J. S. & other authors (2008). Investigations of 2 cases of diphtheria-like illness due to toxigenic *Corynebacterium ulcerans*. *Clin Infect Dis* **46**, 395–401.
- Ueki, S., Fujii, Y., Matsuzawa, H., Takagi, M., Abe, H., Kwee, I. L. & Nakada, T. (2006). Assessment of axonal degeneration along the human visual pathway using diffusion trace analysis. *Am J Ophthalmol* **142**, 591–596, 596.e4.
- Urakawa, T., Matsuzawa, H., Suzuki, Y., Endo, N., Kwee, I. L. & Nakada, T. (2011). Analysis of ascending spinal tract degeneration in cervical spondylotic myelopathy using 3D anisotropy contrast single-shot echo planar imaging on a 3.0-T system. *J Neurosurg Spine* **15**, 648–653.
- Wagner, K. S., White, J. M., Crowcroft, N. S., De Martin, S., Mann, G. & Efstratiou, A. (2010). Diphtheria in the United Kingdom, 1986–2008: the increasing role of *Corynebacterium ulcerans*. *Epidemiol Infect* **138**, 1519–1530.