

Case Report

Acute peritonitis and salpingitis associated with streptococcal toxic shock syndrome caused by Lancefield group G α -haemolytic *Streptococcus dysgalactiae* subsp. *equisimilis*

Toshinobu Horii,^{1,2} Sayuri Izumida,³ Kiyotake Takeuchi,⁴ Toyohiro Tada,⁵ Jinko Ishikawa¹ and Koji Tsuboi⁶

Correspondence

Toshinobu Horii
horiihm@hama-med.ac.jp

^{1,2}Department of Laboratory Medicine¹ and Division of Infectious Diseases and Control², Hamamatsu University School of Medicine, 1-20-1 Handa-yama, Hamamatsu 431-3192, Japan

^{3,4}Department of Clinical Laboratory³ and Department of Obstetrics and Gynecology⁴, Toyokawa City Hospital, 1-19 Koumei-cho, Toyokawa 442-8561, Japan

⁵Department of Pathology, Nagoya City University School of Nursing, Mizuho-ku, Nagoya 467-8601, Japan

⁶Nagoya University School of Health Sciences, 1-1-20 Daiko-minami, Higashi-ku, Nagoya 461-8673, Japan

The authors treated a patient for what appears to be the first reported occurrence of acute peritonitis and salpingitis associated with streptococcal toxic shock syndrome (STSS). This was caused by Lancefield group G α -haemolytic *Streptococcus dysgalactiae* subsp. *equisimilis* TKCH2004-001. The isolate showed M protein type *stc36* and carried the *spegg* gene. To the best of the authors' knowledge, the present report represents the first case of STSS complicating acute peritonitis and salpingitis caused by Lancefield group G α -haemolytic *S. dysgalactiae* subsp. *equisimilis*.

Received 5 January 2006

Accepted 18 March 2006

Introduction

Streptococcus dysgalactiae subsp. *equisimilis* can be classified by a combination of phenotypic and genotypic characterization into various groups: Lancefield group C α -haemolytic, Lancefield group C β -haemolytic, Lancefield group G β -haemolytic and Lancefield group L β -haemolytic *S. dysgalactiae* subsp. *equisimilis* (Vieira *et al.*, 1998). Lancefield group C and G *S. dysgalactiae* subsp. *equisimilis* (GCS and GGS, respectively) account for 5–8% of human streptococcal infections, including bacteraemia, wound infections, otitis media, purulent pharyngitis and streptococcal toxic shock syndrome (STSS) (Bisno *et al.*, 1996; Hashikawa *et al.*, 2004; Keiser & Campbell, 1992; Lopardo *et al.*, 2005; Natoli *et al.*, 1996; Roth *et al.*, 1999; Turner *et al.*, 1993; Wagner *et al.*, 1996; Woo *et al.*, 2001). Streptococci are a rare cause of peritonitis and salpingitis (Berenguer *et al.*, 1992; Stevens *et al.*, 1989; Vuilleumier & Halkic, 2001).

Recently, several cases of STSS caused by GGS have been described (Hashikawa *et al.*, 2004; Woo *et al.*, 2003). Underlying diseases in most patients with GCS- and GGS-related STSS have included diabetes mellitus, malignant neoplasms, cirrhosis and burns (Hashikawa *et al.*, 2004; Lopardo *et al.*, 2005; Wagner *et al.*, 1996; Woo *et al.*, 2003). In the present study, we characterized a clinical isolate of GGS that caused acute peritonitis and salpingitis, with progression to STSS in a patient with a history of endometriosis and resection of an endometriotic ovarian cyst.

Case report

A 43-year-old woman with a history of endometriosis and resection of an endometriotic ovarian cyst was admitted to the Toyokawa City Hospital in July 2004 because of abdominal pain with a sudden mid-menstrual onset. Laboratory results included a white blood cell (WBC) count of $11\,600\text{ mm}^{-3}$, a platelet count of $402 \times 10^9\text{ l}^{-1}$ and a C-reactive protein (CRP) concentration of 6.6 mg l^{-1} . On hospital day 2, shock developed, with hypotension, hypothermia, clouding of consciousness and progressive ascites. In an emergency adnexectomy, the left fallopian tube and ovary were resected. α -Haemolytic *S. dysgalactiae* subsp.

Abbreviations: ARDS, acute respiratory distress syndrome; GCS, group C *Streptococcus dysgalactiae* subsp. *equisimilis*; GGS, group G *Streptococcus dysgalactiae* subsp. *equisimilis*; STSS, streptococcal toxic shock syndrome.

equisimilis TKCH2004-001 was isolated from ascitic fluid. After initiation of treatment with a carbapenem, panipenem (0.5 g intravenously twice daily; Sankyo), three sets of blood samples were collected for aerobic and anaerobic cultures; no isolate was recovered. Pathologic examination of the resection specimen disclosed a ruptured endometriotic cyst of the left ovary. Pus consisting of coccoid organisms, inflammation, and fibrin were present both in the ruptured ovary and the left tube (Fig. 1). The pathologic diagnosis was acute inflammation of the left tube and ovary with exudative serositis and infections with cocci. On hospital day 3, the patient developed acute respiratory distress syndrome (ARDS) and disseminated intravascular coagulation, dying of septic shock on day 5.

S. dysgalactiae subsp. *equisimilis* TKCH2004-001 was identified on the basis of phenotypic analysis (API 20 Strep, bioMérieux Vitek). Lancefield serologic testing (Seroiden Strepto kit; Eiken Chemical) assigned the isolate to group G. The isolate was stored at -70°C in heart infusion broth (Nissui Pharmaceutical) containing 2% Supplement F (Nissui Pharmaceutical) and 20% (v/v) glycerol. Before further testing, the bacteria were inoculated on trypticase soy agar II with 5% sheep blood (TSA II, Nippon Becton Dickinson) and incubated at 37°C overnight. Phylogenetic analysis was performed by 16S rRNA gene (rDNA) sequencing, as described elsewhere (Hashikawa *et al.*, 2004). A 1272 bp sequence was amplified by PCR, corresponding to positions 49–1380 of the 16S rDNA sequences of clinical

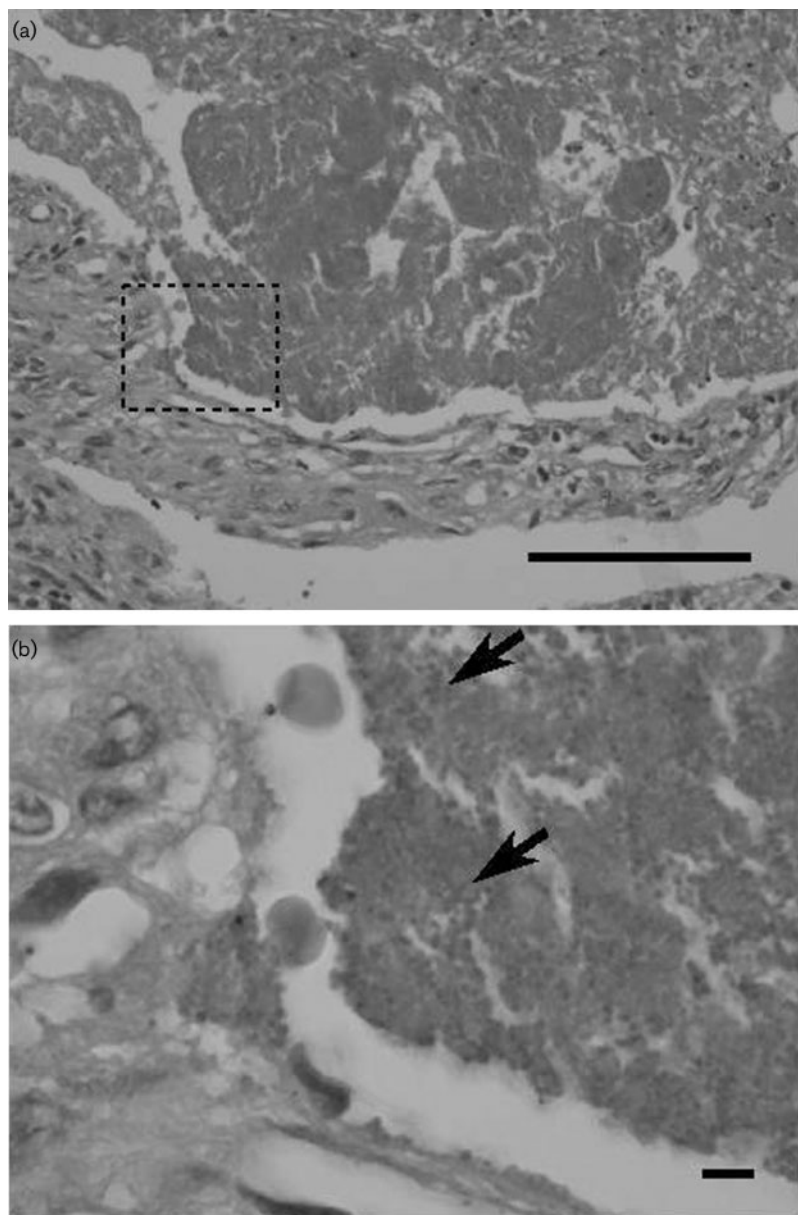


Fig. 1. Histopathologic appearance of cocci (b, arrow) in a meshlike fibrin network in the lumen of the fallopian tube. Panel (b) is a higher-power view ($\times 1700$) of the area delineated by a broken square in (a) ($\times 425$). Haematoxylin and eosin staining. Bar, 100 μm .

isolates of *S. dysgalactiae* subsp. *equisimilis*, including Hiroshima, Fukuoka, A-22-84, A-ka and A-sa strains (Hashikawa *et al.*, 2004). *Sma*I-restricted fragment patterns of chromosomal DNA from the present *S. dysgalactiae* subsp. *equisimilis* TKCH2004-001 and Hiroshima, Fukuoka, A-22-84, A-ka and A-sa were compared by PFGE. The restriction patterns of *S. dysgalactiae* subsp. *equisimilis* TKCH2004-001 and A-22-84 were indistinguishable from each other (data not shown).

MICs were determined by an Etest method (AB Biodisk) in accordance with the manufacturer's instructions. MICs of β -lactams, macrolides and fluoroquinolones for *S. dysgalactiae* subsp. *equisimilis* TKCH2004-001 were as follows: 0.016 $\mu\text{g ml}^{-1}$ for penicillin G, 0.125 $\mu\text{g ml}^{-1}$ for oxacillin, 0.19 $\mu\text{g ml}^{-1}$ for ceftazidime, 0.016 $\mu\text{g ml}^{-1}$ for cefpirome, 0.032 $\mu\text{g ml}^{-1}$ for cefepime, <0.016 $\mu\text{g ml}^{-1}$ for imipenem, 0.064 $\mu\text{g ml}^{-1}$ for clarithromycin, 0.5 $\mu\text{g ml}^{-1}$ for azithromycin, 0.064 $\mu\text{g ml}^{-1}$ for clindamycin and 0.38 $\mu\text{g ml}^{-1}$ for levofloxacin. The M protein type was determined as *stc36* according to an M protein gene (*emm*) typing protocol by the sequencing of the *emm* gene (<http://www.cdc.gov/ncidod/biotech/strep/strepindex.html>). Detection of superantigenic genes was performed by PCR; primers for the *speA*, *speB*, *speC*, *speG* and *speF* genes were designed as described elsewhere (Hashikawa *et al.*, 2004). The *speG* gene, but none of the other superantigenic genes, was detected in *S. dysgalactiae* subsp. *equisimilis* TKCH2004-001.

Discussion

The presently reported patient developed acute peritonitis and salpingitis caused by GGS, with progression to septic shock, ARDS and multiple organ failure. This is compatible with the well-recognized syndrome of STSS (Alouf & Müller-Alouf, 2003; The Working Group on Severe Streptococcal Infections, 1993). *S. dysgalactiae* subsp. *equisimilis* TKCH2004-001 was isolated from ascitic fluid, while three sets of blood cultures following initiation of panipenem administration failed to recover an organism. Underlying diseases included endometriosis with previous resection of an ovarian cyst, an unusual setting for GCS- and GGS-related STSS (Hashikawa *et al.*, 2004; Wagner *et al.*, 1996; Woo *et al.*, 2003). A routine cervical smear examination 1 month previously may have been a risk factor for infection. *S. dysgalactiae* subsp. *equisimilis* TKCH2004-001 showed susceptibility to antimicrobials, including β -lactams, but therapy with panipenem failed to reverse STSS. Streptococci are a rare cause of peritonitis and salpingitis (Berenguer *et al.*, 1992; Stevens *et al.*, 1989; Vuilleumier & Halkic, 2001). Few previous cases of peritonitis involving STSS caused by *Streptococcus pyogenes* have been reported in English (Stevens *et al.*, 1989; Vuilleumier & Halkic, 2001). Thus, to the best of our knowledge, the present report represents the first case of STSS complicating acute peritonitis and salpingitis caused by GGS. The case supports the view that GGS can cause overwhelming septic states.

Both α -haemolytic and haemolysin-deficient isolates of *S. dysgalactiae* subsp. *equisimilis* have been identified phenotypically by the API 20 Strep system as well as genotypically by 16S rDNA sequencing (Dierksen & Tagg, 2000; Woo *et al.*, 2003). Our α -haemolytic isolate, TKCH2004-001, was identified by both methods as *S. dysgalactiae* subsp. *equisimilis*. An earlier study proposed that streptococcal superantigens may be responsible for development of STSS caused by GCS and GGS (Hashikawa *et al.*, 2004). In the present case, *S. dysgalactiae* subsp. *equisimilis* TKCH2004-001 carried the *speG* gene, which is a homologue of the *S. pyogenes* superantigenic gene *speG*, although involvement of *SpeG* in the pathogenesis of GGS-related STSS remains unclear. It would be advisable to determine if the superantigenic genes are actually expressed, since superantigenic genes such as *speB* are found in a number of *S. pyogenes* isolates, although the degree of expression of the genes varies from strain to strain (Nagamune *et al.*, 2005). M protein, known to be a major virulence factor of *S. pyogenes*, inhibits activation of the alternative complement pathway and impedes phagocytosis by polymorphonuclear leukocytes (Campo *et al.*, 1995). Although an earlier study found the M proteins of GCS and GGS isolated from STSS patients to be highly variable (Hashikawa *et al.*, 2004), the M protein type identified in our TKCH2004-001 isolate was *stc36*, which had also been identified in GGS A-22-84, isolated as a causative pathogen from an STSS patient at a location in Japan far from Toyokawa City (Hashikawa *et al.*, 2004). In the present study, the PFGE genotypes of *S. dysgalactiae* subsp. *equisimilis* TKCH2004-001 and A-22-84 were indistinguishable from one another. Our results suggest that it is important to monitor genetically clonal dissemination involving certain GGS among STSS patients.

Acknowledgements

The authors thank Professor Michio Ohta, Department of Molecular Bacteriology, Nagoya University Postgraduate School of Medicine, Nagoya, Japan, for providing GGS Hiroshima, Fukuoka, A-22-84, A-ka and A-sa strains, and for valuable discussions, and Miroku Medical Laboratory, Saku, Nagano 384-2201, Japan, for PFGE analysis. This study was supported by a Grant-in-Aid for Scientific Research (17790353) from the Ministry of Education, Culture, Sports, Science and Technology of Japan.

References

- Alouf, J. E. & Müller-Alouf, H. (2003). Staphylococcal and streptococcal superantigens: molecular, biological and clinical aspects. *Int J Med Microbiol* **292**, 429–440.
- Berenguer, J., Sampedro, I., Cercnado, E., Baraia, J., Rodríguez-Créixems, M. & Bouza, E. (1992). Group-C β -hemolytic streptococcal bacteremia. *Diagn Microbiol Infect Dis* **15**, 151–155.
- Bisno, A. L., Collins, C. M. & Turner, J. C. (1996). M proteins of group C streptococci isolated from patients with acute pharyngitis. *J Clin Microbiol* **34**, 2511–2515.
- Campo, R. E., Schultz, D. R. & Bisno, A. L. (1995). M proteins of group G streptococci: mechanisms of resistance to phagocytosis. *J Infect Dis* **171**, 601–606.

- Dierksen, K. P. & Tagg, J. R. (2000). Haemolysin-deficient variants of *Streptococcus pyogenes* and *S. dysgalactiae* subsp. *equisimilis* may be overlooked as aetiological agents of pharyngitis. *J Med Microbiol* **49**, 811–816.
- Hashikawa, S., Iinuma, Y., Furushita, M., Ohkura, T., Nada, T., Torii, K., Hasegawa, T. & Ohta, M. (2004). Characterization of Group C and G streptococcal strains that cause streptococcal toxic shock syndrome. *J Clin Microbiol* **42**, 186–192.
- Keiser, P. & Campbell, W. (1992). 'Toxic strep syndrome' associated with group C *Streptococcus*. *Arch Intern Med* **152**, 882–884.
- Lopardo, H. A., Vidal, P., Sparo, M. & 8 other authors (2005). Six-month multicenter study on invasive infections due to *Streptococcus pyogenes* and *Streptococcus dysgalactiae* subsp. *equisimilis* in Argentina. *J Clin Microbiol* **43**, 802–807.
- Nagamune, H., Ohkura, K. & Ohkuni, H. (2005). Molecular basis of group A streptococcal pyrogenic exotoxin B. *J Infect Dis* **11**, 1–8.
- Natoli, S., Fimiani, C., Faglieri, N., Laurenzi, L., Calamaro, A., Frasca, A. M. & Arcuri, E. (1996). Toxic shock syndrome due to group C streptococci. *Intensive Care Med* **22**, 985–989.
- Roth, S., Andrassy, K., Schmidt, K.-H., Günther, E. & Ritz, E. (1999). Febrile lady with acute renal failure and desquamatic erythema. *Am J Kidney Dis* **34**, 1–6.
- Stevens, D. L., Tanner, M. H., Winship, J., Swarts, R., Ries, K. M., Schlievert, P. M. & Kaplan, E. (1989). Severe group A streptococcal infections associated with a toxic shock-like syndrome and scarlet fever toxin A. *N Engl J Med* **321**, 1–7.
- The Working Group on Severe Streptococcal Infections (1993). Defining the Group A streptococcal toxic shock syndrome. Rationale and consensus definition. *JAMA (J Am Med Assoc)* **269**, 390–391.
- Turner, J. C., Fox, A., Fox, K., Addy, C., Garrison, C. Z., Herron, B., Brunson, C. & Betcher, G. (1993). Role of group C beta-hemolytic streptococci in pharyngitis: epidemiologic study of clinical features associated with isolation of group C streptococci. *J Clin Microbiol* **31**, 808–811.
- Vieira, V. V., Teixeira, L. M., Zahner, V., Momen, H., Facklam, R. R., Steigerwalt, A. G., Brenner, D. J. & Castro, A. C. D. (1998). Genetic relationships among the different phenotypes of *Streptococcus dysgalactiae* strains. *Int J Syst Bacteriol* **48**, 1231–1243.
- Vuilleumier, H. & Halkic, N. (2001). Streptococcal toxic shock syndrome revealed by a peritonitis. Case report and review of the literature. *Swiss Surg* **7**, 25–27.
- Wagner, J. G., Schlievert, P. M., Assimacopoulos, A. P., Stoeck, J. A., Carson, P. J. & Komadina, P. (1996). Acute group G streptococcal myositis associated with streptococcal toxic shock syndrome: case report and review. *Clin Infect Dis* **23**, 1159–1161.
- Woo, P. C. Y., Fung, A. M. Y., Lau, S. K. P., Wong, S. S. Y. & Yuen, K. Y. (2001). Group G beta-hemolytic streptococcal bacteremia characterized by 16S ribosomal RNA gene sequencing. *J Clin Microbiol* **39**, 3147–3155.
- Woo, P. C. Y., Teng, J. L. L., Lau, S. K. P., Lum, P. N. L., Leung, K.-W., Wong, K.-L., Li, K.-W., Lam, K.-C. & Yuen, K.-Y. (2003). Analysis of a viridans group strain reveals a case of bacteremia due to Lancefield group G alpha-hemolytic *Streptococcus dysgalactiae* subsp. *equisimilis* in a patient with pyomyositis and reactive arthritis. *J Clin Microbiol* **41**, 613–618.