

Case Report

Correspondence

V. A. J. Kempf
volkhard.kempf@med.uni-
tuebingen.de

Received 16 October 2007
Accepted 6 January 2008

Non-tuberculous mycobacterial infection of the parotid gland in an immunosuppressed adult

F. S. Gittinger,^{1,2} A. Raible¹ and V. A. J. Kempf³

¹Medizinische Universitätsklinik I, Eberhard-Karls-Universität Tübingen, Otfried-Müller Str. 10, 72076 Tübingen, Germany

²Medizinische Universitätsklinik I, Martin-Luther-Universität Halle-Wittenberg, Ernst Grube Str. 40, 06120 Halle (Saale), Germany

³Institut für Medizinische Mikrobiologie und Hygiene, Universitätsklinikum Tübingen, Eberhard-Karls-Universität Tübingen, Elfriede-Aulhorn Str. 6, 72076 Tübingen, Germany

Infections of the parotid gland with non-tuberculous mycobacteria (NTM) are rarely described. Here, we report on an infection of the parotid gland caused by *Mycobacterium avium* and give a literature-based overview about this entity. In the light of a global increase of mycobacterial infections, unusual manifestations have to be considered and should be included in the differential diagnosis when dealing with solid lesions of uncertain aetiology in the head and neck region.

Introduction

Infections with non-tuberculous mycobacteria (NTM) are registered worldwide with increasing frequency (Danielides *et al.*, 2002; Saggese *et al.*, 2003). NTM are known to cause asymptomatic infections and symptomatic disease. Most often, pulmonary infection is encountered; however, infections of lymphatic tissues, skin and soft tissue and, moreover, disseminated courses of infection have been reported. NTM lymphadenitis often presents as cervical lymphadenitis (mainly in young children aged 1–5 years) encompassing lymphatic tissue of the submandibular, submaxillary and preauricular region (Saggese *et al.*, 2003; Hazra *et al.*, 1999). Infected children usually do not present any signs of immunodeficiency (Losurdo *et al.*, 1998). Over the last few years, a remarkable increase of NTM lymphadenitis in adults and children has been registered (Saggese *et al.*, 2003; Grange *et al.*, 1995). Reasons contributing to this surge are most probably (i) the increase in the number of immunosuppressed patients and (ii) improvements in diagnostic methods thereby facilitating the diagnosis of such infections.

Case report

We report a case of NTM-associated parotitis in a 76-year-old female adult. On admission, the patient presented with a large lump of the left preauricular parotid region, which had developed during the previous 6 weeks. Otalgia had been present for 1 year and no other symptoms were present. Over the previous 5 years, she had been treated for chronic rheumatic polyarthritis with steroids (5.0 mg per day) but had received no further immunosuppressive treatment. Notably, the patient suffered from diabetes mellitus type II due to steroids.

Physical examination revealed a $\sim 2 \times 2$ cm preauricular lump of the left parotid without fluctuation. Tenderness or facial palsy were not present. The overlying skin showed no signs of inflammation. Saliva obtained from the gland was clear, and fistulae were not present. No enlarged cervical lymph nodes were palpable.

A magnetic resonance imaging (MRI) scan of the head and neck region (Fig. 1) showed a $2.0 \times 1.9 \times 1.8$ cm large tumour located at the upper part of the left parotid gland. In both native and contrast-enhanced scans, the lesion presented as a necrotic ring-like enhancing lesion with subcutaneous location and minimal stranding of adjacent subcutaneous tissue. In contrast to the rest of the tumour, the caudal region did not demark itself clearly against the surrounding gland. Ipsilateral lymph nodes were not significantly enlarged. Particularly in light of the short generation time, the differential diagnosis encompassed a malignancy (e.g. a mucoepidermoid tumour with central necrosis).

A complete parotidectomy with sparing of the facial nerve was performed. Preparation of the tumour for histological assessment revealed the tumour to be filled with pus. Microscopy revealed a small granuloma with Langerhans giant cells and epithelioid cells present in both the parenchyma and in an intraparotid lymph node. Rod-shaped bacteria were visible by Ziehl–Neelsen staining. These were cultivated in the BD MGIT 960 system (Becton Dickinson) and identified as *Mycobacterium avium* using the Genotype TB identification system (Hain; Nehren).

A computed tomography (CT) scan of the lung and testing for mycobacteria in sputum and gastric fluid samples proved to be negative. Unfortunately, neither tuberculosis skin testing nor an interferon-release assay (e.g. QuantiFERON Gold; Cellestis) were performed at any time during the stay.

Abbreviation: NTM, non-tuberculous mycobacteria.

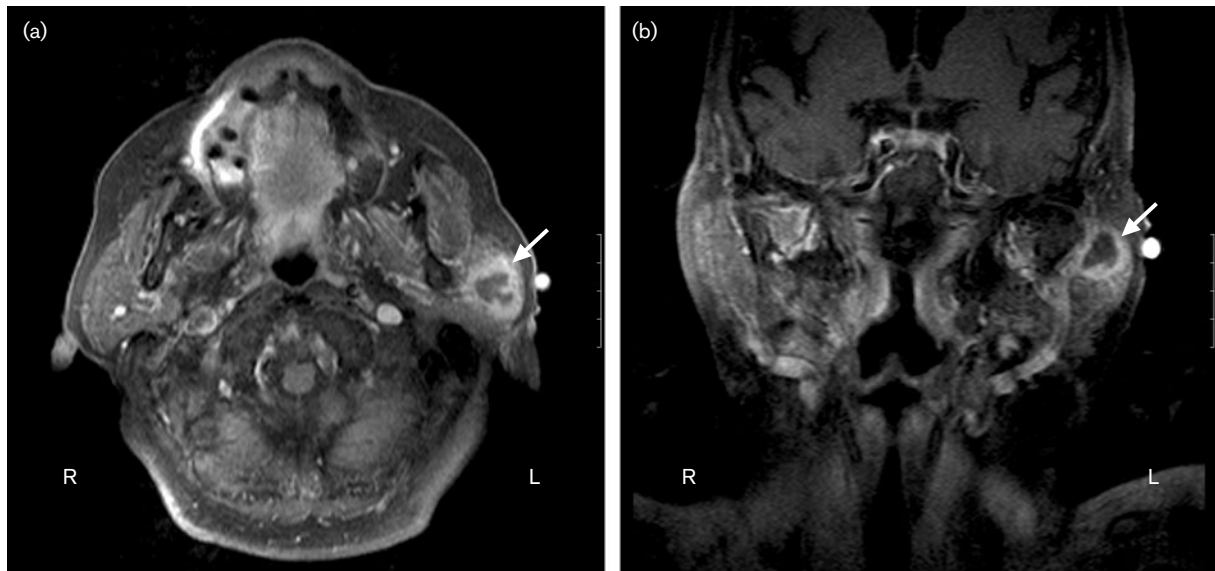


Fig. 1. MRI scan of the head and neck region of the patient after intravenous application of gadolinium-diethylenetriamine-pentaacetic acid. The tumour-like lesion is located in the upper region of the left parotid gland and appears to have a central necrosis. (a) Horizontal section; (b) longitudinal section.

The patient recovered well from surgery and minimal facial palsy of the oral region disappeared within a few weeks. She was treated for 6 months with rifabutin and clarithromycin without any signs of recurrence of the NTM infection. Immunosuppression with corticosteroids could not be reduced any further due to persistent polyarthritis.

Discussion and review of the literature

Parotitis caused by NTM is a rare disease, usually affecting young children. In contrast, patients suffering from a parotitis caused by *Mycobacterium tuberculosis* are predominantly adults (Süoğlu *et al.*, 1998; Kim *et al.*, 2005). So far, NTM infections of the parotis in adults have been mostly reported in association with an underlying HIV infection, either due to immunosuppression related to the virus itself or in connection with an immune reconstitution disease (Lawn *et al.*, 2005).

The herein described patient did not suffer from an HIV infection; however, she was immunosuppressed due to a rheumatoid arthritis treated with steroids. Such steroid medication has been proven to lead to an increased risk for contracting tuberculosis and this risk apparently increases when glucocorticoid treatment exceeds a physiological dosage. In a case-control study, it was demonstrated that patients have an approximately threefold increased risk of contracting tuberculosis when treated with 15 mg per day or less prednisolone or its equivalents and the association is independent of other risk factors, such as underlying pulmonary disease, smoking or diabetes (Jick *et al.*, 2006). In addition, diabetes is also a well-recognized risk factor for

developing a parotitis, most probably due to changes in composition of saliva, duct obstruction and reduced immunity (Thiede *et al.*, 2002).

NTM lymphadenitis of the head and neck region is predominantly found in children and, in some cases, the infections involve salivary glands (e.g. the parotid gland; Saggese *et al.*, 2003; Rieu *et al.*, 1990; Panesar *et al.*, 2003). In most cases of parotitis, *M. avium* is the causative pathogen (Grange *et al.*, 1995; Rieu *et al.*, 1990; Tunkel, 1995); however, singular cases caused by *Mycobacterium fortuitum*, *Mycobacterium scrofulaceum* or *Mycobacterium chelonae* have also been reported (Lawn *et al.*, 2005; Chen *et al.*, 2007; Tunkel & Romaneschi, 1995). In adults, NTM infections of the parotid gland are rare; most often a concomitant HIV infection is present (Lawn *et al.*, 2005; Benharrats *et al.*, 1998). Clinically, the usually unilateral infection presents as a swelling or an initially firm mass in the parotid region which develops in a short period of time ranging from 1 week to 4 months (Shah & Haddad, 2004; Robson *et al.*, 1999). Untreated, the firm masses may soften and fluctuation can be palpated; these often tumour-like lesions are usually non-tender (Robson *et al.*, 1999). When the course of infection progresses, the overlying skin may get involved, resulting in a violaceous discoloration (Panesar *et al.*, 2003; Robson *et al.*, 1999; Kvaerner *et al.*, 2001). Fistulae can form and discharge pus (Panesar *et al.*, 2003; Tunkel & Romaneschi, 1995) and uni- or bilateral cervical lymphadenitis might be observed. Fever, cough, weight loss or systemic symptoms are often not present and, in most cases, a chest radiograph proves to be without pathological findings (Tunkel & Romaneschi, 1995; Shah & Haddad, 2004).

Diagnosis of NTM parotitis is usually made by fine-needle aspiration, thereby obtaining material for histopathology and microbiological diagnosis (Tunkel, 1995, 1999; Tunkel & Romaneschi, 1995; Griffith *et al.*, 2007). However, this procedure has been reported to cause skin breakdown and chronic infections may ensue (Cox *et al.*, 1995). Nevertheless, fine-needle aspiration can result in an early diagnosis of NTM parotitis (Tunkel, 1995) or can at least exclude a malignancy (Kvaerner *et al.*, 2001). A further, controversially discussed and less well described mode of NTM-infection diagnosis is represented by an intradermal skin test for mycobacteria using purified bacterial proteins (Saggese *et al.*, 2003; Kvaerner *et al.*, 2001). Additional imaging (e.g. CT or MRI scans) may help to obtain signs of a NTM infection. In MRI scans, lesions caused by NTM infections usually present as subcutaneous necrotic, ring-enhancing lesions with typically minimal stranding of subcutaneous fat (Robson *et al.*, 1999). Thickening of the overlying skin may also be observed (Bagla *et al.*, 2003).

Therapeutically, complete surgical excision is considered more effective than antibiotic treatment alone (Shah & Haddad, 2004; Lindeboom *et al.*, 2007). In a recent study, the rate of complete regression of NTM infections was 96 % when the infected tissues were removed surgically; in contrast, antibiotic treatment alone led to a complete regression of the infection in only 66 % of the cases (Lindeboom *et al.*, 2007). Treatment failure could not be explained on the basis of patient non-compliance or *in vitro* resistance of NTM to clarithromycin or rifabutin. However, in a few cases, lymphadenitis caused by NTM has been shown to respond well exclusively to antibiotic treatment or in combination with abscess drainage (Losurdo *et al.*, 1998; Chen *et al.*, 2007; Green *et al.*, 1993; Luong *et al.*, 2005). The number of published cases is limited, however, and in some cases surgery still had to be performed due to persistent infection (Panesar *et al.*, 2003). Antibiotic treatment prior to surgery can reduce the size of the lesion to be excised and lessens the inflammation, thus ameliorating the surgical outcome (Danielides *et al.*, 2002; Shah & Haddad, 2004). Postoperative antibiotic treatment can also reduce the risk of a recurrence of NTM infection although surgery appears to remove the causative infection in most cases (Tunkel, 1995; Tunkel & Romaneschi, 1995). This latter fact should be taken into account when extensive disease is present (Saggese *et al.*, 2003). Finally, antimycobacterial treatment, when used, should consist of a clarithromycin-based multi-drug regimen (Hazra *et al.*, 1999; Losurdo *et al.*, 1998; Shah & Haddad, 2004; Griffith *et al.*, 2007; Berger *et al.*, 1996).

In our patient, the mode of transmission remains unclear. However, in regard to the infected site, ingestion of the pathogens appears to be a likely entry portal. NTM are widely distributed in the environment (von Reyn *et al.*, 2002), being found, for example, in soil, water and food. NTM infections appear to be acquired from environmental exposure (von Reyn *et al.*, 1993) as no evidence of a zoonotic or human-to-human transmission exists (Ahrens *et al.*, 1995; Tanaka *et al.*, 2000). Pathogens are thought to infect humans by entering

small intradermal lesions or by incidental ingestion (Saggese *et al.*, 2003). Ingestion is also thought to be one of the reasons why small children contract NTM-associated infections of the head and neck region more frequently than adults because this patient group is more prone to place bacterially contaminated objects in their mouth (Falworth & Simpson, 1996). Infection of the salivary glands may result from a retrograde passage of mycobacteria along the duct (Cox *et al.*, 1995). So far, complete surgical excision of infected areas is proposed to be the most effective therapy. As at admission a malignancy was suspected in our patient, a complete resection of the parotid gland and infected site was performed, probably leading to the clearance of the NTM infection.

The case report described here should serve as a reminder that due to the increase in NTM infections and the advances in immunosuppressive therapeutic regimens, infection with NTM has to be considered when dealing with lesions of unclear origin.

References

- Ahrens, P., Giese, S. B., Klausen, J. & Inglis, N. F. (1995). Two markers, IS901–IS902 and p40, identified by PCR and by using monoclonal antibodies in *Mycobacterium avium* strains. *J Clin Microbiol* **33**, 1049–1053.
- Bagla, S., Tunkel, D. & Kraut, M. A. (2003). Nontuberculous mycobacterial lymphadenitis of the head and neck: radiologic observations and clinical context. *Pediatr Radiol* **33**, 402–406.
- Benharrats, I., Jacob, L. & Taulera, O. (1998). Parotitis due to *Mycobacterium* and HIV infection. *Rev Med Interne* **19**, 676–677.
- Berger, C., Pfyffer, G. E. & Nadal, D. (1996). Treatment of nontuberculous mycobacterial lymphadenitis with clarithromycin plus rifabutin. *J Pediatr* **128**, 383–386.
- Chen, C. C., Chen, S. Y., Chen, Y. S., Lo, C. Y. & Cheng, P. W. (2007). *Mycobacterium fortuitum*-induced persistent parotitis: successful therapy with clarithromycin and ciprofloxacin. *Head Neck* **29**, 1061–1064.
- Cox, H. J., Brightwell, A. P. & Riordan, T. (1995). Non-tuberculous mycobacterial infections presenting as salivary gland masses in children: investigation and conservative management. *J Laryngol Otol* **109**, 525–530.
- Danielides, V., Patrikakos, G., Moerman, M., Bonte, K., Dhooge, C. & Vermeersch, H. (2002). Diagnosis, management and surgical treatment of non-tuberculous mycobacterial head and neck infection in children. *ORL J Otorhinolaryngol Relat Spec* **64**, 284–289.
- Falworth, M. S. & Simpson, M. T. (1996). Cervical lymphadenitis in children: the role of *Mycobacterium avium-intracellulare*. *Br J Oral Maxillofac Surg* **34**, 511–514.
- Grange, J. M., Yates, M. D. & Pozniak, A. (1995). Bacteriologically confirmed non-tuberculous mycobacterial lymphadenitis in south east England: a recent increase in the number of cases. *Arch Dis Child* **72**, 516–517.
- Green, P. A., von Reyn, C. F. & Smith, R. P. (1993). *Mycobacterium avium* complex parotid lymphadenitis: successful therapy with clarithromycin and ethambutol. *Pediatr Infect Dis J* **12**, 615–617.
- Griffith, D. E., Aksamit, T., Brown-Elliott, B. A., Catanzaro, A., Daley, C., Gordin, F., Holland, S. M., Horsburgh, R., Huitt, G. & other authors (2007). An official ATS/IDSA statement: diagnosis, treatment, and

prevention of nontuberculous mycobacterial diseases. *Am J Respir Crit Care Med* 175, 367–416.

Hazra, R., Robson, C. D., Perez-Atayde, A. R. & Husson, R. N. (1999). Lymphadenitis due to nontuberculous mycobacteria in children: presentation and response to therapy. *Clin Infect Dis* 28, 123–129.

Jick, S. S., Lieberman, E. S., Rahman, M. U. & Choi, H. K. (2006). Glucocorticoid use, other associated factors, and the risk of tuberculosis. *Arthritis Rheum* 55, 19–26.

Kim, Y. H., Jeong, W. J., Jung, K. Y., Sung, M. W., Kim, K. H. & Kim, C. S. (2005). Diagnosis of major salivary gland tuberculosis: experience of eight cases and review of the literature. *Acta Otolaryngol* 125, 1318–1322.

Kvaerner, K. J., Kvestad, E. & Orth, M. (2001). Surgery required to verify atypical mycobacterial infections. *Int J Pediatr Otorhinolaryngol* 61, 121–128.

Lawn, S. D., Checkley, A. & Wansbrough-Jones, M. H. (2005). Acute bilateral parotitis caused by *Mycobacterium scrofulaceum*: immune reconstitution disease in a patient with AIDS. *Sex Transm Infect* 81, 517–518.

Lindeboom, J. A., Kuijper, E. J., Bruijnesteijn van Coppenraet, E. S., Lindeboom, R. & Prins, J. M. (2007). Surgical excision versus antibiotic treatment for nontuberculous mycobacterial cervicofacial lymphadenitis in children: a multicenter, randomized, controlled trial. *Clin Infect Dis* 44, 1057–1064.

Losurdo, G., Castagnola, E., Cristina, E., Tasso, L., Toma, P., Buffa, P. & Giacchino, R. (1998). Cervical lymphadenitis caused by nontuberculous mycobacteria in immunocompetent children: clinical and therapeutic experience. *Head Neck* 20, 245–249.

Luong, A., McClay, J. E., Jafri, H. S. & Brown, O. (2005). Antibiotic therapy for nontuberculous mycobacterial cervicofacial lymphadenitis. *Laryngoscope* 115, 1746–1751.

Panesar, J., Higgins, K., Daya, H., Forte, V. & Allen, U. (2003). Nontuberculous mycobacterial cervical adenitis: a ten-year retrospective review. *Laryngoscope* 113, 149–154.

Rieu, P. N., van den Broeck, P., Pruszczyński, M., de Wilde, P. C. & Festen, C. (1990). Atypical mycobacterial infection of the parotid gland. *J Pediatr Surg* 25, 483–486.

Robson, C. D., Hazra, R., Barnes, P. D., Robertson, R. L., Jones, D. & Husson, R. N. (1999). Nontuberculous mycobacterial infection of the head and neck in immunocompetent children: CT and MR findings. *AJNR Am J Neuroradiol* 20, 1829–1835.

Saggese, D., Compadretti, G. C. & Burnelli, R. (2003). Nontuberculous mycobacterial adenitis in children: diagnostic and therapeutic management. *Am J Otolaryngol* 24, 79–84.

Shah, M. B. & Haddad, J. (2004). Nontuberculous mycobacteria-induced parotid lymphadenitis successfully limited with clarithromycin and rifabutin. *Laryngoscope* 114, 1435–1437.

Süoğlu, Y., Erdamar, B., Çölhan, İ., Katircioğlu, O. S. & Çevikbas, U. (1998). Tuberculosis of the parotid gland. *J Laryngol Otol* 112, 588–591.

Tanaka, E., Kimoto, T., Matsumoto, H., Tsuyuguchi, K., Suzuki, K., Nagai, S., Shimadzu, M., Ishibatake, H., Murayama, T. & Amitani, R. (2000). Familial pulmonary *Mycobacterium avium* complex disease. *Am J Respir Crit Care Med* 161, 1643–1647.

Thiede, O., Stoll, W. & Schmal, F. (2002). Clinical aspects of abscess development in parotitis. *HNO* 50, 332–338.

Tunkel, D. E. (1995). Atypical mycobacterial adenitis presenting as a parotid abscess. *Am J Otolaryngol* 16, 428–432.

Tunkel, D. E. (1999). Surgery for cervicofacial nontuberculous mycobacterial adenitis in children: an update. *Arch Otolaryngol Head Neck Surg* 125, 1109–1113.

Tunkel, D. E. & Romaneschi, K. B. (1995). Surgical treatment of cervicofacial nontuberculous mycobacterial adenitis in children. *Laryngoscope* 105, 1024–1028.

von Reyn, C. F., Waddell, R. D., Eaton, T., Arbeit, R. D., Maslow, J. N., Barber, T. W., Brindle, R. J., Gilks, C. F., Lumio, J. & other authors (1993). Isolation of *Mycobacterium avium* complex from water in the United States, Finland, Zaire, and Kenya. *J Clin Microbiol* 31, 3227–3230.

von Reyn, C. F., Arbeit, R. D., Horsburgh, C. R., Ristola, M. A., Waddell, R. D., Tvaroha, S. M., Samore, M., Hirschhorn, L. R., Lumio, J. & other authors (2002). Sources of disseminated *Mycobacterium avium* infection in AIDS. *J Infect* 44, 166–170.